THE VAGINAL RADICAL OPERATION

LANDAU

Ex Libris
Sir John W. Byers

THE HISTORY AND TECHNIQUE

OF THE

VAGINAL RADICAL OPERATION.

BY

PROF. DR. LEOPOLD LANDAU AND DR. THEODOR LANDAU,

OF BERLIN.

English Translation by

B. L. EASTMAN, M.D.,

ASSISTANT IN THE LANDAU FRAUEN-KLINIK, BERLIN; EX-INTERNE, COUNTY HOSPITAL, CHICAGO; FELLOW OF THE BRITISH GYNÆCOLOGICAL SOCIETY,

AND

ARTHUR E. GILES, M.D.,

B.Sc. LOND., M.R.C.P. LOND., F.R.C.S. ED.,

ASSISTANT-SURGEON, CHELSEA HOSPITAL FOR WOMEN, LONDON.

LONDON:

BAILLIÈRE, TINDALL AND COX,

20 & 21, KING WILLIAM STREET, STRAND.

PARIS AND MADRID.

1897.

PREFACE

TO THE GERMAN EDITION.

To-day the knife is the emblem of gynæcological treatment; it has supplanted the aromatic fomentation, mercurial inunction, and the painting of the long-suffering portio, which ruled the therapy of diseases of women until within a few decennia. Simultaneously with the invention of the various operations, the field of indications for them was widened indefinitely. Several years ago Noeggerath gathered up a long and melancholy list of diseases in which Emmet's operation was indicated. Trachelorrhaphy was the curative remedy for the following conditions, to mention but a few out of the twenty-six: Prolapse of the uterus and vagina, retroversion and flexion of the uterus, epilepsy, dementia, and salivation. At least the published reports stated so. And was it any different with the indications for castration and amputation of the cervix?

The success of these operations for the given indications was proved by the authors by means of imposing lists of patients who, under the protection of asepsis and the tolerance of the female genitalia, had escaped with their lives. The 'scientific' basis for the real value of an operation developed *pari passu* with the operative lust, until it reached the simple formula:—Mortality of the operation in 100-200 cases = 0; therefore it is not a dangerous operation, and hence it must be good. The permanent success, permanent cure, the only real standard of the worth of the operation, underwent complete atrophy during this 'rage for numbers.'

Often enough the suggestive effect of an operation did not last as long with the patient as did the auto-suggestion upon the inventor of the operation; and just as with the 'malade

imaginaire' of an earlier time, the 'médecin imaginaire' of to-day also needs his Molière. Thus, it is not surprising that one operation 'having the most excellent results' is shortly replaced by another 'still more effective,' and that each operation is alarmingly short-lived.

Is it any wonder that the practitioner, after trying in vain to keep pace with the changing play of the operation-inventor, the over-hasty varieties, combinations and confusion of the operations and indications, finally becomes discouraged by the mass of argument and contradiction, and turns his back on all operative measures? Then he necessarily goes to the other modern extreme, and becomes a therapeutic nihilist. Certainly, such a therapy is more in accord with the real duties of the thoughtful physician than is the operative furore of some of our enthusiastic technicians.

What is the practitioner to think of the gynæcologist who, for instance, makes the uncomplicated displacement of the womb an excuse for dangerous operative measures? On the other hand, it is hardly necessary to point out how false it were to go to extremes in the other direction, and strike out all operative manipulation from the field of gynæcology.

The justification of any surgical measure must depend on its fulfilling two conditions: first, that the disease in question is not capable of cure by a simpler means, nor of spontaneous cure. Second, that the patient can be thoroughly and permanently relieved of his suffering by the proposed operation. If both conditions can be fulfilled, the operation is thus legitimatized, and in fact, in a surgical sense, forms the specific therapy for this particular disease.

We regard the hystero-salpingo-oöphorectomy, which we call the *vaginal radical operation*, as such an operation. This is what we make use of in the treatment of double inflammatory or suppurative diseases of the tubes and ovaries, a class of cases which resists every other method of treatment.

This advocacy of, and enthusiasm for, such a radical and severe operation may seem strange as coming from us, since in speech and writing we have so continuously warned against operative meddlesomeness, against intra-uterine injection, castration of neurotics, cervix amputation, and ventro- and vagino-fixation of the uterus. Compared with the radical

extirpation of the entire internal genitalia, does not the removal of the adnexa by the less dangerous (?) cœliotomy represent an easier and more effective method? No, neither easier nor more effective.

The mere removal of both inflamed or suppurating appendages, whether through the vagina or through the belly, with separation of adhesions to the intestines, or even with the introduction of oil into the peritoneal cavity, may give good immediate results, but the permanent cure does not follow. The women recover from the operation, but not from their disease, because only one portion of the diseased structures is removed, while the real source and origin of the affection, the diseased uterus, is left behind to light up the old trouble again at any time.

Such experiences, which we also have had after the simple removal of tubes and ovaries, have robbed these partial, really incomplete operations of their hold, for us at least, and have demonstrated that it is better, for the patient, to complete the work in hand instead of doing it piecemeal. In fact, it is better in such cases not to operate at all than to do so but imperfectly.

The words of the ancient poet are strikingly appropriate here:

> 'Curando fieri quædam majora videmus
> Vulnera, quæ melius non tetigisse foret.'

It is exactly the permanent results achieved by the vaginal radical operation in the disease of the adnexa which demonstrate its superior value over the mere salpingo-oöphorectomy.

It is well known that the immediate results of this operation are also good. In the past few years we have had many opportunities of reporting from time to time the cases operated on by this method, and particularly the results attained in the treatment of complicated pelvic abscesses.

This book is written in response to the gratifying interest which the profession has shown in these methods, and in deference to those attending the operations in our clinic who have so often expressed the desire to have an accurate description of our operative technique. The work, describing as it does the methods which we practise for the vaginal

extirpation of the internal genitalia, is intended as a text-book of this operation.

In following out this didactic purpose, we have had to dispense with a short continuous description of the method. We have explained in a general way, first, the ground principles of our technique, and then, in a second part, we have described each individual method in detail, with special reference to its indications. Each procedure is explained individually, and in this way the work is intended as a book of reference for the surgeon. Naturally, certain repetitions are unavoidable—in fact, necessary.

Further, we hope that the illustrations embodied in the text will add to its instructive value, and represent more clearly the different stages, varieties, and subvarieties of the operation.

We have partly employed a diagrammatic form of illustration, but many of the plates represent photographs taken during the different steps of the operation.

In order to dispose of the criticism that our classification was only theoretical, a number of specimens acquired by the various methods have been put together again, and photographed from nature. They are intended to explain the indication for, and the description of, the corresponding method, to prove that it is really practical, and to enliven the theoretical discussion. For the same reason we have added clinical and pathological data concerning each specimen so illustrated.

In arranging the specimens, as well as in the preparation of the work itself, we were especially aided by our assistant, Dr. Ludwig Pick.

As a prelude to the technique of the operation, we have given an outline of its history. In this we were actuated by the view that the development of the operation itself affords a series of illustrations of its aims and advantages. In this sense, therefore, the historical survey may be considered as a part of the general technique of the operation.

LEOPOLD AND THEODOR LANDAU.

BERLIN.

PREFACE

TO THE ENGLISH EDITION.

In bringing this work before the English-speaking members of the profession, we have been actuated by the knowledge that no such detailed and complete description of the vaginal operation has as yet appeared in our language. In this we have received the support and encouragement of English and American doctors attending the lectures and operations at the Landau clinic.

There is no question but that the total extirpation of the internal sexual organs for tubal and pelvic suppuration is a radical procedure. It is radical, and it is just this quality which makes the operation peculiar to itself, and gives it its intrinsic value in the treatment of these diseases. After all, pus and granulation tissue in the female pelvis are not so greatly different from like products when existing in other cavities of the body, and when their removal is demanded, why should not as vigorous measures be employed here as elsewhere? Those who follow the literature and attend the discussions pertaining to cases of this class must be convinced that there is everywhere a striving for more thorough and complete work in this line, as evidenced by the attention paid to ligature material, stump exudates, toilet of the peritoneum, and the ever-recurring question of drainage. The drift is more and more toward radicalism, and the question at present is not why, but how. Hardly anyone denies the desirability, or, indeed, necessity, of radical measures, but the technique has been the stumbling-block and the barrier hitherto.

And herein is exactly the value of the Landaus' work—the great simplicity and yet completeness of the technique which they have developed and practised, and lately described in detail.

This is not the place for statistics, hence it will suffice to say that the mortality of the vaginal total extirpation is *less* than that of abdominal salpingectomy. The permanent results are incomparably better. What more is necessary?

The desire to place the technique before the profession in a readable and connected form is the origin of the German as well as of the English edition. We can only hope that in its new form it will meet with the same favour as the original has.

Our sincere thanks are due to Professor Landau for his many kindnesses during this work, and during the whole service of one of us in his clinic; also to Dr. Theodor Landau for the literature which he has placed at our disposal, and for his personal aid in the translation.

B. L. EASTMAN, BERLIN.
ARTHUR E. GILES, LONDON.

May, 1897.

CONTENTS.

PART I.

THE DEVELOPMENT OF THE VAGINAL RADICAL OPERATION.

CHAPTER		PAGE
I.	HISTORY OF REMOVAL OF THE UTERUS UP TO THE TIME OF PÉAN	11
II.	PÉAN'S IMPROVEMENTS—PÉAN'S OPERATION	16
III.	THE FURTHER ADOPTION OF PÉAN'S OPERATION—ITS INDISCRIMINATE USE—DEVELOPMENT OF THE VAGINAL RADICAL OPERATION	19
IV.	THE VAGINAL RADICAL OPERATION: ITS DEFINITION, LIMITS, INDICATIONS, AND ADVANTAGES—THE PRINCIPLES AND TECHNICAL AIDS OF OUR OPERATION	22
V.	THE VAGINAL RADICAL OPERATION IN A BROADER SENSE	32

PART II.

TECHNIQUE OF THE VAGINAL RADICAL OPERATION.

A.—GENERAL CONSIDERATIONS.

I.	OUR OPERATION: THE ENUCLEATING PROCEDURE—THE SO-CALLED CLAMP METHOD—QUALITIES AND ADVANTAGES OF THE CLAMPS	35
II.	NON-CLOSURE OF THE ABDOMINAL CAVITY—MECHANISM OF THE HEALING	40
III.	MORCELLEMENT	45
IV.	CLASSIFICATION, MECHANISM AND METHOD OF PERFORMANCE OF THE MORCELLATING OPERATIONS	46
V.	MORCELLEMENT AND HÆMOSTASIS	51
VI.	OUR CLASSIFICATION OF THE VAGINAL RADICAL OPERATION ACCORDING TO ITS USES—THE INDICATIONS BASED UPON TOPOGRAPHICAL ANATOMY	53

B.—SPECIAL TECHNIQUE.

I.	PREPARATION OF THE PATIENT—THE ANÆSTHETIC, THE ASSISTANTS, ETC.	55
II.	ARMAMENTARIUM: INSTRUMENTS AND DRESSINGS	60

CHAPTER PAGE

III. TECHNIQUE OF THE VARIOUS FORMS OF THE OPERATION—REMOVAL OF THE APPENDAGES AND MOBILE UTERUS WITHOUT MORCELLEMENT - - - - 68
FIRST STAGE: EXPOSING AND FIXING THE PORTIO 68
SECOND STAGE: CIRCULAR INCISION OF THE PORTIO—VARIOUS INCISIONS—EXPLORATORY INCISION 71
THIRD STAGE: FREEING THE UTERUS FROM THE PERICERVICAL TISSUE—THE ANATOMICAL RELATIONS OF THE BLADDER AND URETERS TO THE GENITAL ORGANS - - - 77
FOURTH STAGE: OPENING THE PERITONEAL CAVITY 86
FIFTH STAGE: LUXATION OF THE UTERUS AND ADNEXA INTO THE VAGINA - - - 88
SIXTH STAGE: HÆMOSTASIS AND EXCISION—THE NUMBER OF CLAMPS AND METHOD OF THEIR APPLICATION - - - - - 93
SEVENTH STAGE: REVISION OF THE WOUND—INTRODUCTION OF THE GAUZE—PROCEDURE IN CASE OF A TOO LARGE OR TOO SMALL OPENING IN THE VAGINAL VAULT - - - 104

IV. REMOVAL OF THE ADNEXA AND ADHERENT UTERUS WITHOUT MORCELLATION - - - - - 112

V. REMOVAL OF THE UTERUS AND APPENDAGES WITH THE AID OF MORCELLEMENT—SPLITTING THE UTERUS—MEDIAN SECTION OF ONE WALL - - - 121

VI. COMPLETE MEDIAN SECTION OF THE UTERUS - - 128

VII. MORCELLATING OPERATIONS (TRUE MORCELLEMENT) - 135

VIII. BILATERAL SECTION OF THE UTERUS, AND TRANSVERSE EXCISION UNDER PRIMARY HÆMOSTASIS (PÉAN'S CLASSICAL MORCELLEMENT) - - - - 144

IX. IRREGULAR MORCELLATION (TRUE MORCELLEMENT) - 150

X. THE DIFFERENT FORMS OF IRREGULAR MORCELLEMENT EMPLOYED ON THE ENLARGED UTERUS - - 155

XI. THE AVOIDANCE OF HÆMORRHAGE AND INJURY TO NEIGHBOURING ORGANS DURING MORCELLEMENT - - 159

XII. COMBINED METHODS - - - - - - 161

PART III.

THE AFTER-TREATMENT.

I. AFTER-FEEDING: REGULATION OF BOWELS AND BLADDER—TEMPERATURE—SECONDARY HÆMORRHAGE - 165

EXPLANATIONS OF THE ILLUSTRATIONS - - - 173
LIST OF THE ILLUSTRATIONS - - - - ix

LIST OF ILLUSTRATIONS.

FIG.		PAGE
1.	OPERATING-TABLE, SLIGHTLY ELEVATED. IN THE VAGINAL RADICAL OPERATION THE LEG-HOLDERS ARE TO BE REMOVED - - - - -	57
3-16.	VAGINAL RADICAL OPERATION APPLIANCES -	62, 63, 65
17.	FIXING THE PORTIO VAGINALIS - - -	69
18.	COMMENCEMENT OF THE CIRCULAR INCISION ON THE ANTERIOR SURFACE OF THE CERVIX, THE NECK BEING DRAWN OUT OF THE VULVA WITH VOLSELLÆ -	72
19.	DIAGRAM OF THE COURSE OF THE URETERS (LUDWIG PICK) - - - - - -	82
20.	INTRODUCTION AND SPREADING OF THE SCISSORS IN OPENING THE UTERO-VESICAL POUCH - -	87
21.	EVULSION OF THE FUNDUS FROM THE PELVIC CAVITY	89
22.	OPENING THE POUCH OF DOUGLAS BY THRUSTING A FORCEPS THROUGH FROM ABOVE - - -	91
23.	UTERUS, WITH THE APPENDAGES OF BOTH SIDES, DRAWN DOWN INTO THE VAGINA; THE RIGHT APPENDAGES SEIZED WITH AN OVARIAN FORCEPS -	92
24, 25.	APPLICATION OF CLAMPS FROM BELOW, DIAGRAMMATIC (DR. VOGEL) - - - -	95, 96
26, 27.	THE DANGER OF APPLYING THE CLAMPS PARTLY FROM ABOVE AND PARTLY FROM BELOW, DIAGRAMMATIC (DR. VOGEL) - - - -	97, 98
28.	APPLICATION OF THE FIRST CLAMP ON THE RIGHT ADNEXA, THE LEFT FOREFINGER BEHIND THE RIGHT BROAD LIGAMENT - - - - -	100
29.	CLAMPING OF THE OTHER SIDE, ACCORDING TO THE FIRST METHOD - - - - -	102
30.	EXPOSURE AND SPREADING OUT OF THE WOUND BY THE CLAMPS AND RETRACTOR - -	106

FIG. PAGE

31. INTRODUCTION OF THE CENTRAL STRIP OF GAUZE - 109
32. PREVENTIVE CLAMPING OF THE LEFT UTERINE VESSELS 118
33. FIXATION OF THE PORTIO VAGINALIS FOR ANTERIOR MEDIAN SECTION - - - - - 124
34. THE UNROLLING OF THE UTERUS RESULTING FROM SECTION OF ITS ANTERIOR WALL - - - 125
35. THE DELIVERY OF THE ADNEXA OF BOTH SIDES AFTER COMPLETE MEDIAN SECTION OF THE UTERUS - 131
36, 37. THE TWO POSITIONS OF THE LEFT BROAD LIGAMENT AFTER COMPLETE MEDIAN SECTION OF THE UTERUS (DR. VOGEL) - - - - 132, 133
38. APPLICATION OF THE CLAMPS ON THE LEFT SIDE IN THE POSITION SHOWN IN FIG. 36 - - - 134
39, 40. VAGINAL RADICAL OPERATION WITH COMPLETE MEDIAN SECTION OF THE UTERUS - - - 136, 137
41. MORCELLATION OF THE ANTERIOR WALL OF THE UTERUS BY REMOVAL OF VERTICAL STRIPS - - 139
42. DOYEN'S METHOD OF MORCELLEMENT (AFTER DOYEN) 141
43. SEGOND'S METHOD OF MORCELLEMENT—FINAL STAGE 142
44. IRREGULAR MORCELLEMENT OF A UTERUS ONLY SLIGHTLY ENLARGED - - - - 152
45. CENTRIPETAL MORCELLEMENT OF A FIBROID OF THE BODY OF THE UTERUS - - - - 158
46. VAGINAL RADICAL OPERATION BY THE MIXED PROCEDURE - - - - - - 162
47. ABDOMINO-VAGINAL RADICAL OPERATION - - 163

PART I.

THE DEVELOPMENT OF THE VAGINAL RADICAL OPERATION.

CHAPTER I.

HISTORY OF REMOVAL OF THE UTERUS UP TO THE TIME OF PÉAN.

THE technique of the removal of the womb, with its appendages, has acquired an undreamed-of perfection in the last few years, and the indications for the operation have been greatly extended. The advances made in the technique furnish in certain classes of diseases a more certain, and in many the only, method of cure. The severest inflammatory diseases of the internal genital organs, all the benign and the greater part of the malignant tumours of and about the uterus, have been brought within reach of the surgeon's knife, whilst in two other respects the removal of the womb represents an important advance in the science of gynæcological surgery.

Firstly, the development of vaginal hysterectomy has brought to our knowledge the great value of hysterectomy as an exceedingly efficient means of abdominal drainage. Secondly, single steps of the operation have branched off from the path along which the modern method of extirpation was developing, and have become independent, conservative vaginal operations. At the same time we must admit that with regard to these latter—anterior and posterior vaginal cœliotomy, vagino-fixation, etc.—their indications

have been enormously extended, and their real value greatly over-estimated.

The advance in the technique of uterus extirpation seems for the present to have reached a resting-point; and as it has been our intention for some time to describe our method in full, the present seems a fitting occasion, and in the following pages we shall enumerate the principles and details of the vaginal extirpation of the uterus and appendages as practised by us. The abdominal and combined operations will be discussed in another place.

In this work the description of the technique will naturally include a consideration of the scope and indications of the vaginal operation. Theoretical discussion, except when based on our observation and experience, will be omitted. Inasmuch as we regard our position in this matter as being new and original, we must necessarily review the development and history of extirpation of the uterus.

The beginning of this development dates from the time of the publications of Freund[1] (1878) and Czerny[2] (1879). Previous to this time only isolated and tentative efforts had been made by a few daring operators, each time to be brought to a halt by the general opinion of the profession, expressed in speech and writings. Excepting inversion of the uterus, for which Ambroise Paré[3] as early as 1575 performed an extirpation — probably but partial — carcinoma alone, on account of its frequency and its fatal course, could induce the surgeon to take up the knife, and then only as a last resort. There is no doubt that the early procedures for extirpation of the uterus were so nearly complete and perfect that technically the vaginal operation of to-day has not very much new to offer. In 1809 Struve[4] proposed the following operation for carcinoma uteri: 'to prolapse and draw the womb down with a forceps, separate the vaginal portion by means of a circular incision, ligature the vessels, and sever the womb from the ligaments'—a good representation of

[1] W. A. Freund, Volkmann's 'Sammlung klinischer Vorträge,' No. 133.
[2] Czerny, 'Wiener med. Wochenschrift,' 1879, Nos. 46, 49.
[3] A. Franchomme, 'Journal des sc. méd. Lille,' June 1, 1895.
[4] 'Hufeland'sche Journal,' Band 16, St. 3, p. 123.

the ligature method now in use. Ten years later followed Langenbeck's celebrated publication,[1] and the opinion of his opponents was embodied in the merciless criticism of Johann Jörgs immediately afterwards. Even the partial excision of the uterus, which was recommended at about the same time, especially by Osiander, received but little favour from him. Subsequent attempts were purely sporadic, and were associated with the names of Wolf, Sauter, Blundel, Recamier, Roux, Paletta, von Siebold, Dubled, C. Wenzel, Gendrin, Gutberlet, and Delpech. The methods used were as different as the writers themselves. One operated with the ligature, another employed punk or charpie as a hæmostatic; one operated only upon prolapsed uteri, a second produced this artificially, and a third operated with the organ *in situ;* some employed the vaginal method, others exclusively the abdominal, whilst others, again, combined the two. And what did all their efforts accomplish? For the answer let us read Dieffenbach.[2]

This the greatest German surgeon of his time says in the chapter on the extirpation of the uterus: 'To take the entire womb from the belly of a woman means the removal of that woman's soul, even if it be a diseased soul, a thought at which every human being quakes. The extirpation of the whole uterus, an organ so important to the female organism, is really as great an operation as the removal of the spleen, kidney, or any other diseased organ. Still, some daring men have attempted it, and they deserve our thanks, inasmuch as the results of their terrible operations furnish us all the proof needed to banish this procedure from the field of surgery. . . . According to my opinion, an indication for this operation does not exist. The attempted extirpations of the womb partake more of the character of murder tales than of curative surgical operations.' Again (p. 799): 'The principle is entirely false when we try to bestow the full rights of surgical citizenship on any great operation

[1] Theodor Landau, 'Totalexstirpation d. krebsigen Gebärmutter,' 1893.

[2] J. Fr. Dieffenbach, 'Die operative Chirurgie,' Bd. 2, pp. 794-799, 1848.

merely because somebody has once survived it. Sauter had the good fortune to have a patient recover, from whom he had removed the uterus; all other patients, however, have reaped nothing but death, and this, too, after suffering from the most frightful of all diseases, and undergoing the most terrible operation. Further massacres of this sort must not be attempted, even with the help of sulphuric ether. What has succeeded at one time will not necessarily do so again. If the English coachman recovered after a carriage-pole had been driven right though his chest, or the American sailor lived after an anchor-hook had penetrated his belly, it was only by a chance, harder to secure than to win the grand prize in a lottery. No doubt the awful reports will not prevent some surgeon from devising a new method of extirpating the uterus; much better it would be if someone would teach us how to cure cancer of the womb with medicine. Methods of extirpating the uterus easier than the ones now in use will hardly be discovered; for the inaccessibility of this organ, its important connections, and the disease itself, will always remain the same. Other and better incisions are not possible, and the severest injuries of the neighbouring organs (such as the bladder) often occur in the most experienced hands. Finally, the dreadful result of these procedures suggested to surgeons the unfortunate idea of removing the diseased uterus through the abdomen, and yet the greater part of the operation had to be made from below. Speedy death for the patient was the result of this undertaking. It is to be hoped that the terrible eminence to which this operation has now attained will be the cause of its eternal ruin.'

Through such terrifying warnings all surgical efforts directed to the removal of the uterus fell into disrepute, and the paucity of the adherents of hysterectomy during the following decade is easily accounted for. All the more honour therefore to those who, in spite of all opposition, and when confronted with the most hopeless of diseases, carcinoma, had the courage of their convictions, and, undismayed even by their own unfavourable results, strove by word and deed for the perfecting and extension of their operation.

In the history of the extirpation of the uterus, Kieter (1848) and Reiche[1] (1854) deserve mention, the latter especially, who operated seven times. Although none of his patients lived more than a few weeks, yet he strenuously advocated the repetition of total extirpation with the aid of chloroform, which was then just coming into use. But the operation was not yet ready for revival, and in 1874 Hegar and Kaltenbach[2] once more condemned it. 'In the last few years total extirpation has not been performed, not only because the former methods have been discarded as being too dangerous, but because the cases which offer even a slight chance of success after such an energetic operation are extremely rare.'

Now begins the new era in the history of hysterectomy—an era stamped with the names of W. A. Freund and Czerny. One of the chief difficulties in the way of the surgeon had been the view that cancer was a dyscrasia; for, according to this theory, the removal of the tumour could only be regarded as a useless beginning. Virchow's researches destroyed the foundation of this idea, and carcinoma now came to be recognised as a disease primarily local—a disease therefore susceptible to local treatment, and indeed curable. At about the same time, the new principles of wound treatment introduced by Pasteur and Lister offered fresh encouragement to operative measures, which had been previously hopeless. All procedures directed to the extirpation of the uterus seemed henceforth justified, if it were possible to overcome the purely technical difficulties; and here it was that Freund's work laid the foundations of abdominal hysterectomy, as did Czerny's for the vaginal operation. The types which they gave us then have remained types ever since, and have lost nothing of their originality, nothing of their effectiveness. And this in spite of a great series of modifications, as the most important of which we consider Bardenheuer's abdominal drainage, and Doyen's ingenious modification bearing on the separation of the bladder and ureters from the genital tract in the abdominal extirpation. Freund's earliest communications on total extirpation of the uterus gave us, in a

[1] Reiche, 'Exstirpatio uteri,' 'Deutsche Klinik,' Bd. 6, p. 484, 1854.

[2] Hegar and Kaltenbach, 'Operative Gynäkologie,' third edition, p. 217, 1886.

finished and elaborated form, the important fundamental principles of the technique for all further abdominal or abdomino-vaginal procedures—namely, formation of the pedicles from the broad ligaments, their inversion into the vagina, and, finally, transference of the whole wound surface from abdomen to vagina, changing it from intra- to extra-peritoneal. Freund deserves all the more credit from the fact that he tested and successfully executed his method under the most technically unfavourable circumstances—the abdominal total extirpation of a cancerous uterus, which was purulent, fixed, and not enlarged.

The extension of the indications for the vaginal operation has kept pace with its rapid adoption, so that total extirpation is now employed not only for carcinomata, but also for myomata and for uncontrollable idiopathic uterine hæmorrhage without gross anatomical lesions.

CHAPTER II.

PÉAN'S IMPROVEMENTS—PÉAN'S OPERATION.

PÉAN'S[1] attempt to do away with all sutures for the control of hæmorrhage, and to use clamps instead, was an improvement of very great importance in the technique of the vaginal operation. He had repeatedly employed this form of hæmostasis in other operations[2]; but the first time he used it upon the uterus to the exclusion of the older method was on August 21, 1885, for the removal of a cancerous womb. A year later, July 21, 1886, after many attempts to combine the clamp and the suture methods, he formally advocated the former method of hæmostasis as a distinctive principle in total hysterectomy.[3] Richelot's name also should be associated with this method; his part in the development of hæmostasis by forcipressure is best given by himself in the paper read by him before the French Surgical Congress, October 19, 1886. He said: 'In the employment of the

[1] 'Bullet. de la Soc. de Chirurg.,' November 11, 1885.
[2] 'Leçons de Clinique Chirurgicale,' 1876.
[3] 'Gaz. des Hôpit.,' April 20, 1889.

clamps, I know that I have made no new discovery, and my claim of priority is limited to the following point: Systematic and exclusive use of them in place of all ligatures, this not for the sake of convenience or in difficult cases, but in every case as the method of election.' As a fact, Péan had occasionally used the ligature or the ligature and clamp method between August, 1885, and July 21, 1886; Richelot not since July 8, 1886.

Spencer Wells (1882) and Jennings (1885)[1] have been considered by some writers as the originators of hæmostasis by forcipressure as applied to hysterectomy; but, as we intend to show, M. B. Freund[2] is really the projector of this important advance. After a series of experiments on the cadaver, he recommended theoretically, in 1881, the use of clamps in the place of sutures and ligatures. 'The difficulties in the way of handling the broad ligaments suggested the thought of securing them, in their continuity, with suitable compression forceps which could remain in place for a time.' 'These instruments are similar to the Péan forceps; but, to prevent their slipping, one blade is provided with a groove, into which fits a convexity on the opposite blade. They are introduced from the vagina, and clamped on to the broad ligament at each side, lying close to and parallel with the uterus.' 'The experiment of allowing these to lie for several days in the pelvic cavity' seemed to Freund quite permissible.

In this connection it is also worthy of notice that, in the same work (1881), he mentions a method especially adapted to the removal of the cancerous womb—a method that has since been 'discovered,' nobody knows how many times: the use of the actual cautery. He used this first to incise the vaginal vault, and then, after the clamps were in place, to sever the broad ligaments inside the forceps.

In France the method of using clamps in hysterectomy rapidly gained many adherents, such as Bouilly, Quénu, Terrier, Segond, Michaux, Nélaton, Doyen, etc. In other

[1] Pozzi, 'Gynécologie,' p. 401, 1890.
[2] 'Zeitschrift f. Geburt. u. Gynäk.,' Bd. 6, 1881.

countries, Mueller[1] of Switzerland and L. Landau[2] were among the first to advocate the plan.

Since then, outside of our own school in Germany, we have found but few advocates of this procedure; whilst in many articles, from numerous opponents, a few weak and theoretical objections to the method periodically appear. It is only the use of the clamps that has extended the indications for the vaginal operation previously based on the Czerny method, and a uterus immobilized by carcinomatous or inflammatory infiltration can now be removed by the vaginal route regardless of these complications, and without having recourse to extensive accessory procedures.[3]

Then Péan's morcellement, which this surgeon brought into use more than thirty years ago for the removal of large deep-seated abdominal tumours, showed us the way of overcoming the difficulties attendant on the vaginal extirpation of enlarged uteri. So, from the two improvements introduced by Péan, the clamp and morcellement, the rather limited field of the old (Czerny) suture method was broadened in every direction in a manner and extent corresponding to the advances in the methods.

At first the total extirpation of the cancerous womb was undertaken only when one had to deal with a mobile organ of normal size, in which the malignant growth was limited strictly to the uterus. Gradually, however, in the same way and under the same conditions—mobility, normal size—the operation began to be adopted in certain cases for prolapse, small myomata, and uncontrollable hæmorrhage from the endometrium. Then, with the aid of Péan's improvements, the list of operable cases was enlarged to include immobile and enlarged uteri regardless of the causal factor—myoma, carcinoma, etc.

And now it is Péan who again appears on the scene with a third important modification of the technique of vaginal hysterectomy, an improvement which makes the extirpation

[1] 'Centralblatt f. Gynäk.,' 1882, No. 12.

[2] 'Berlin klin. Wochenschrift,' 1888, No. 10.

[3] L. Landau, Internat. Med. Congress, Vol. III., Part viii., p. 51, *et seq.*, 1891.

of the uterus not only a direct, but also an indirect curative operation. *With Péan originated the removal of the uterus as a remedy for diseases of the adnexa.*

CHAPTER III.

THE FURTHER ADOPTION OF PÉAN'S OPERATION—ITS INDISCRIMINATE USE — DEVELOPMENT OF THE VAGINAL RADICAL OPERATION.

WITH a few words more we will complete the history of Péan's operation. Among those who assisted in its introduction and further employment, the names of Segond and Doyen stand out pre-eminently. Others working along this line were Richelot, Bouilly, Nélaton, Quénu, Reclus, and Routier in France; Jacobs, Rouffart, and Debaisieux in Belgium; Iversen in Denmark; Treub in Holland; Acconci, Bastianelli, Inverardi, Ruggi in Italy; L. and Th. Landau in Germany. Of other German operators favouring this or the clamp method we know only C. Abel, Räther, and Schramm up to the present time.

The Brussels International Gynæcological Congress, September, 1892, marks an important epoch in the development of this procedure. Here for the first time the question of 'Péan's operation' was brought before a large body of specialists, and thoroughly and extensively discussed. An evidence of its wide adoption since that time is to be seen in Lafourcade's dissertation in 1893, in which he cites 138 cases collected from various sources.[1]

At that time, however, in spite of the rapidly-accumulating literature on the subject, and in spite of the valuable systematizing, it was difficult from the published reports to estimate clearly the real value of the operation, or to defend it against the many objections urged by its opponents. The one common feature of the individual communications of the

[1] J. Lafourcade, 'De l'hystérectomie vaginale dans les suppurations Périutérines.' Thèse de Paris, 1893.

writers often consisted in the discussion of the technique, to the neglect of the other points involved; their writings were mostly in the form of collective reports, details being almost or entirely neglected. The most striking of all was the vague and hazy manner in which the indications were considered; the overworked term 'pelvic suppuration' was on duty everywhere, and was apparently considered quite sufficient.

Under this title were included a host of other pelvic suppurative diseases besides the 'suppurations graves périutérines' for the cure of which Péan had devised this operation. Certainly many unimportant and many actually non-suppurative cases were subjected to this operation, and it seemed that the less the organs were diseased, the more readily were they extirpated.

The indications given, loosely expressed as 'pelvic suppuration,' were always devoid of a definite pathologico-anatomical basis; there was but little attempt at individualization; in other words, the exact clinical diagnosis was omitted. This criticism does not spring from a mania for theoretical classification, but is the recognition of the fact that only from a proper sorting of the cases can a suitable differential system of treatment be established.

On these three points—the pathologico-anatomical classification of pelvic abscesses, their clinical diagnosis, and their wholly individual treatment—we have already insisted in a series of articles published elsewhere.[1]

In classifying these diseases anatomically, without regard to their specific origin or to the nature and method of infection and diffusion, the intra- are to be distinguished from the extra-peritoneal abscesses. Under the latter are those in preformed cavities (pyometra, pyosalpinx, pyo-ovarium), and those lying within a tissue, paravaginal and parametric cellular tissue, and pelvic and abdominal subperitoneal connective tissue. They may be single or multiple, and are often bilateral. The two forms are seldom found separate; usually

[1] L. Landau, 'Arch. f. Gynäkol.,' Band 46, Heft 3. 'Berliner Klin. Woch.,' No. 22-24, 1894. 'Tubensäcke,' Berlin, 1891.

intra- and extra-peritoneal abscesses occur side by side. Subperitoneal pelvic cellulitis is generally associated with an inflammation of the overlying peritoneum, forming in this way the first stage of intra-peritoneal abscesses.

The varieties of acute pelvic peritonitis are the serous, fibrinous, purulent, and hæmorrhagic. Chronic adhesive pachypelviperitonitis often occurs alone as a result of the above, or in combination with serous cysts, or with encapsulated intra- and extra-peritoneal abscesses. From these forms of inflammatory and suppurative pelvic peritonitis there are developed various combinations, all of which are susceptible of diagnosis and of differential treatment.

In the above conditions L. Landau (*loc. cit.*) has called attention to the different clinical signs, and has especially used and recommended exploratory puncture and incision into the vaginal vault as diagnostic aids. By their use we were enabled to solve the mystery of that venerable and intangible 'parametric disease' as well as parametric indurations and chronic parametritis, and place them in their proper category. Many a parametric tumour whose stony hardness might have justified the diagnosis of uterine enlargement, or even fibroid, has in this way been demonstrated to be an encapsulated intra-peritoneal abscess, a thickened pyosalpinx or an extra-peritoneal abscess with a dense capsule.

From the clinical and anatomical data at hand, we propose the following basis and outline of treatment for the so-called 'pelvic suppuration':

1. Sharp distinction to be made between unilateral and bilateral diseases, and between single and multiple abscesses.

Removal of the uterus *only in case of bilateral suppuration and destruction of the adnexa.*

2. Incision of *solitary* abscesses, from vagina or abdomen, according to their location.

In case of multilocular abscess involving one side only, removal of the corresponding diseased appendages.

3. For bilateral unilocular abscesses simple incision is first to be tried. This procedure, even in double unilocular pyosalpinx, when unsuccessful, does not complicate any

operation which may later become necessary, and may preserve important functions.

4. In bilateral disease of the appendages with multilocular pus collections (double multilocular pyosalpinx, tubal abscess associated with intra- and extra-peritoneal abscesses, etc.) the mere extirpation of the adnexa by the abdominal or vaginal route is not to be advised, for recovery from the operation does not guarantee recovery from the disease. In these cases, and also in bilateral abscesses with fistulous communication with neighbouring organs, the *vaginal radical operation*—that is, the total extirpation of the uterus and appendages (by the vaginal route alone, whenever possible)—finds its special application.

CHAPTER IV.

THE VAGINAL RADICAL OPERATION: ITS DEFINITION, LIMITS, INDICATIONS, AND ADVANTAGES—THE PRINCIPLES AND TECHNICAL AIDS OF OUR OPERATION.

THE method proposed and employed by us in the treatment of the cases above mentioned is the one we designate as the vaginal radical operation (the castration utéro-ovarienne, utéro-annexielle or totale of French authors). The cases in which, as a last resource, we first tried the operation were *complicated pelvic abscesses.*

A detailed description of the peculiarities of these cases, the results obtained by this method, and the relation of this to other methods of removal of the uterus, have been given by us in previous writings (*loc. cit.*).

A review of these reports must convince every unprejudiced reader that the operation was employed upon patients who were otherwise practically incurable, cases in which any other operation would have been unusually dangerous, and for which, therefore, the vaginal radical operation was the final and only remedy. In all these cases the disease was of several years' duration; many had previously undergone various operations with temporary benefit, incision, resection

of the uterus, laparotomy, etc. Several of these women had fistulæ communicating with bladder and rectum. For such conditions the operation was the only efficient procedure: it was the method of necessity, not of choice.

We next employed the vaginal radical operation in cases of *uncomplicated* bilateral suppurative disease (such as pyosalpinx and suppurating ovarian cysts), when attempts at conservative medical and surgical treatment had failed, instead of the mere removal of the appendages alone. We were led to this, not by theoretical considerations, but by the experience gained in a series of 141 laparotomies for inflammatory disease of the adnexa. This series included 63 cases of pyosalpinx, 38 of hydrosalpinx, 6 of hydro-pyosalpinx, 10 of non-suppurative salpingitis, and 24 of tubal pregnancy, with a total mortality of 6. Of the fatal cases, two were operated on for diffuse peritonitis.

At first we limited the indications more strictly, and employed the vaginal extirpation only in the severest cases; but later on, in all cases of *uncomplicated* bilateral suppurative adnexitis, whenever extirpation was indicated we proceeded at once with this operation. Moreover, besides the first series of cases mentioned, those, namely, with complicated pelvic abscesses, we had had seven cases of severe inflammatory though non-suppurative disease of the appendages, and of tubal pregnancy, with grave bilateral chronic inflammatory changes. In all these, laparatomy would have been an exceedingly difficult procedure. All recovered after the vaginal operation.

These, together with the many suppurative cases mentioned, established for us the indications for the vaginal radical-operation, and determined its use not only as an operation of necessity as in complicated pelvic abscesses, but also as an elective procedure in uncomplicated suppurative and non-suppurative disease of the adnexa, whenever and wherever it was proved that *both* sides were involved.

Why do we substitute the vaginal for the abdominal procedure, since we have sufficiently tested the latter?

In the first place, the permanent cure of the patient is of much greater concern to us than merely having her recover

from an operation. The removal of the inflamed adnexa by the abdominal route, notwithstanding its excellent immediate results, is really curative in only a certain degree. That is, but 60 to 70 per cent. of the cases so treated are permanently relieved of the troubles for which they were operated upon; they have survived the operation, but are not capable of working or enjoying life; the diseased appendages have been taken away, but the patient is not cured. The womb and the adnexal stumps remain, and as the endometritis, metritis and parametritis are cured in only a certain proportion of the cases, these organs form a starting-point for recurrent pelvic peritonitis, and a point of entry for further peritoneal infections. Old inflammations light up again, pyogenic bacteria cause exudations in and about the ligated stumps, or the process takes on a more chronic fibro-plastic character, leading to the formation of intestinal and omental bands. These are the sources of the pain and distress — constipation, chronic ileus—so often occurring in patients who have undergone laparotomy, troubles which only removal of the uterus can either prevent or cure.

Even if the inflammatory processes in and about the uterus are cured after the appendages of both sides have been removed, it still remains to be shown that the atrophying uterus can serve any useful purpose whatsoever in the female economy. On the contrary, a long series of observations enables us to assert positively that the post-operative secondary symptoms are less after total extirpation than after the mere removal of the appendages. From a physiological standpoint, therefore, we have no scruples about removing the womb when operating for bilateral inflammatory or suppurative disease of the appendages, or even in case of bilateral ovarian tumours. In such cases the uterus is for us a negligible quantity, and, apart from other considerations, is removed to secure drainage, exactly as one sacrifices a portion of a sound rib in empyema, or a piece of the skull in draining a brain abscess.

True, a pharisaical conservatism declares the removal of this organ a sin, an organ which is of no possible use, and which often causes damage curable only by a later

extirpation. The uterus, when freed from its appendages, is merely a muscular portion of the abdominal wall, especially dangerous as a site for the entrance and cultivation of virulent bacteria, and later for the development of malignant tumours.

In abdominal laparotomy for inflammatory or suppurative processes, the greatest caution sometimes fails to prevent the contamination of the ventral wound or the peritoneum by the infectious material. The bacteria remaining in the shreds of adhesions in the parametric and subperitoneal tissue are still another source of infection. Abscess of the abdominal wall, localized peritonitis, indurations and fistulæ, furnish sufficient proof of this statement. In the vaginal operation, even when infectious material does come into contact here and there with peritoneum or gut about the field of operation, the conditions are much more favourable. The peritoneum has retained its vitality, and has not been so bruised and maltreated during the operation. Frequently in the vaginal procedure the intestine is not even seen, much less handled. Only the peritoneum in the immediate vicinity is disturbed, and only the organs which are diseased and require removal, or those structures in immediate contact with them, are handled.

If we lay particular stress on the absence of the abdominal scar after the vaginal operation, it is not from æsthetic reasons, but on account of the predisposition to hernia and prolapse of the bowel afforded by such cicatrices. Unfortunately, with any known method of suture we can do but little to ensure against this unhappy complication; indeed, the hernia may occur in a stitch-hole alongside the healed and solid line of the incision. Such ruptures are not infrequently the cause of grave disturbances, especially when omentum and gut are adherent to the scar, and later to the sac, as is often the case after operation for septic troubles. Neither this sequel nor keloid, of which every operator with a large experience has had instances, has as yet been observed in the scar left after vaginal extirpation.

The amount of disturbance caused by the operation itself, as well as the risk of infection, is much less in the vaginal

operation. The manipulation of peritoneum and gut, with fingers, instruments, or dry or wet sponges, and the pulling, displacing, and cooling of the viscera, are done away with. The intestines are only interfered with when they come directly into the field of the operation. Operative shock is avoided, convalescence is easier than after the abdominal operation, and its duration is relatively and absolutely shortened.

And does not the vaginal operation exactly meet the requirements of the universal surgical principle which demands open drainage for all inflammatory or suppurative processes? In no case of vaginal extirpation do we close the peritoneal sac; the wound cavity is loosely packed with strips of gauze about the clamps, and between them and the intestines. All secretions escape into the vagina, for it is the most dependent point, as well as the natural outlet. Drainage is easy and certain, and much more efficient than is ever possible by the abdominal route.

Another important point in this process, to which M. Landau has called attention, is the exceedingly rapid encapsulation about the gauze which occurs on all sides by means of the formation of adhesions and new membrane. In this way the wound cavity shuts itself off from that of the peritoneum to the best advantage, and the rapidly-forming secretion and demarcation occur extra-peritoneally. In draining from the abdomen, the drainage tract is undoubtedly closed off in the same rapid manner, but here the new membranes are in a less natural and less desirable position. Definite adhesions between all the adjacent abdominal organs must be the result, so also with the abdomino-vaginal drainage which Chaput[1] recommends especially for hysterectomy. It is a method which offers, when compared with vaginal drainage, nothing but disadvantages, while the latter is of itself complete and satisfactory.

It must also be borne in mind that the mode of procedure of the vaginal radical operation allows of the termination of the operation at any point, and especially in the first stages, just as well as ventral laparotomy. Further, exploratory

[1] 'Sem. médic.,' p. 349, 1892.

incision or removal of one of the appendages only, in case of mistaken diagnosis of bilateral disease, is carried out easily and without danger by this method. In short, the procedure can be made as conservative as may be desired. Naturally, in certain cases where the process is not of too severe a nature (such as tubal pregnancy or simple salpingitis), the uterus can be drawn forward, the appendages (one or both) isolated and removed, and the womb then replaced, all without any very great technical difficulty. But, on the other hand, it must not be forgotten that in most cases the diagnosis can be ascertained before operation by palpation, aspiration, and observation of the patient, without resorting to an exploratory incision. At least the localization and the inflammatory or suppurative nature of the disease should be established, and the operation chosen in harmony with the diagnosis. From many recent publications, it would seem that in not a few instances it was only after the beginning of the operation—the so-called diagnostic incision—that patients have required treatment at the hands of gynæcologists.

A last objection, and one that is repeatedly urged against the vaginal method, is that inflamed, purulent, and firmly-adherent adnexa can be completely removed only by ventral laparotomy, and that their extirpation per vaginam can therefore always be only partial. Indeed, Péan's identification of his operation with the castratio uterina would seem to strengthen this argument, and to mark this procedure in every case of diseased appendages as imperfect.

Even if this were so, the objection would be silenced by the fact that in a large number of cases the mere removal of the uterus suffices for the certain and permanent cure of the patient, because after resection of the womb the adnexa become completely atrophied. Secondly, Péan and Segond rightly view hysterectomy as the essence of their operation, and not only recommend total castration, but practise it as well.

As a matter of fact, the father of this method (Péan) in all his writings leaves the removal of the appendages to the operator's discretion after the uterus is out of the way. And

Segond also states emphatically that, after the removal of the uterus for adnexal diseases, the appendages themselves are only to be extirpated when this can be done easily and under full visual control.

This was another point to which we directed our efforts in building up this operation; like Doyen, though independently, we demanded the radical execution of the vaginal operation as such, that is, the removal per vaginam in every case, not only of the diseased womb, but of the appendages—pyosalpinx, ovarian abscess—and the intra- and extra-peritoneal abscess walls. The radical extirpation of the diseased tissue must here be regarded as a fundamental principle, and the authors were so convinced of this that in their early operations abdominal laparotomy was combined with the vaginal procedure in cases where the radical operation could not have been completed by the vaginal route alone.

We were first brought to this radical method of operation by theoretical considerations, whose correctness was later proved by the results of certain cases so treated. Where, after the mere removal of the uterus, pus cavities are left in and about the diseased adnexa, the involution of this pathological tissue may be delayed, or, more seldom, may even not occur at all. Suppurating fistulæ persist for months; and even after the vaginal wound has healed, the pelvi-peritonitic inflammation may light up again about the remaining necrotic débris and abscess tissue, with the formation of thick-walled and tense cysts or new abscesses. Complete recovery occurs then only after spontaneous or artificial evacuation.

Indeed, in certain cases the patient is cured only by a later abdominal laparotomy, which, to fulfil the radical principle, should have been directly combined with the vaginal method in the primary operation, instead of being neglected. The greater the mass of abscess wall, pyosalpinx, or ovarian tissue left to be eliminated by its own efforts, the more extensive is the necrosis and demarcation, the greater is the resorption of fever-producing elements, and the more serious is the danger of secondary hæmorrhage from the erosion of larger bloodvessels In such cases a radical operation would

have rendered convalescence shorter and easier, and made the cure more certain.

The cases of complicated pelvic abscesses first treated by us—cases for which Péan and Segond had recommended merely removal of the uterus—showed in a striking manner that our emphasizing the radical procedure in the vaginal operation was not compassed by an empty demand for something ideal.

It is clear that a radical operation is of double importance for exactly those cases having the gravest symptoms and pathological changes; after an incomplete extirpation, or hysterectomy alone, the elements likely to disturb the course of recovery can develop all the more easily.

One cannot deny that in some isolated cases any further procedure than the removal of the uterus, the abdominal radical operation included, simply means death to the patient. Still, as a rule, with a suitable technique it is possible to bring down and extirpate along with the uterus even the most extensively diseased appendages. Two years ago, in describing the method, we reported an extensive series of cases, and demonstrated the corresponding specimens.[1] In this way the possibility of the radical procedure in the simple as well as in the grave cases has been theoretically established, and a large number of operations by others besides ourselves has furnished sufficient practical evidence. Against these facts, will the objection hold good that the extirpation of severely-diseased adnexa is only possible by the abdominal route, and that their removal per vaginam must always be incomplete?

We wish here to call attention to the fact that we have repeatedly published the results of our method, including a series of demonstrations of the operation, of the preparations so obtained, and an accurate history of the patients. Our reason for referring to this is that Doyen, who upholds the same principle of total extirpation, has made no detailed report of his cases; hence a comparison of his cases with ours in the above manner is not possible. Doyen, among his first series (seventy-seven cases) was often obliged to leave

[1] L. Landau, Congress of the Germ. Gyn. Soc., Vienna, 1895.

portions of the adnexa behind, and in four cases portions of the uterus as well.[1] Segond also acknowledges that, up to the time of his employment of the method of morcellement, he also was occasionally compelled to leave fragments of the uterus within the patient's abdomen.

For our part, we consider the entire removal of the womb possible in *every* case. The motive for Péan's and Segond's self-imposed limitation of the operation in grave suppurative cases, to a mere extirpation of the uterus, is certainly to be found in their own technique, which demands, among other things, that nothing be undertaken except under direct visual control.

Contrary to this, we designed and still practise puncture and enucleation by palpation, as well as the removal of the adnexa in the same way, and consider it indispensable for the radical procedure. In this way (palpatory enucleation) it is surprisingly easy to remove the appendages, even when enormously enlarged.

Those who on theoretical grounds assert that such a procedure is contrary to good surgical principles need only consider a parallel case—for instance, ventral laparotomy for pus-tubes or ovarian abscesses adherent deeply in the pelvis. Here, in spite of all Trendelenberg positions, these organs or tissues must be removed blindly, *i.e.*, wholly by touch. And will it occur to somebody else to reject version or the obstetrical forceps simply because the parts that are so manipulated are invisible ?

In the endeavour to remove *all* the diseased tissue, we were justified by the leading principles and the details of our technique, which is materially different from that of Péan and Segond. Since 1887, in all our hysterectomies for carcinoma, the complete freeing of the diseased organ has methodically preceded the arrest of hæmorrhage, and this fundamental principle of the technique was brought into the vaginal radical operation. Thus, the order of procedure is : First of all enucleation of everything that is to be extirpated, then formation of the pedicle, and finally hæmostasis immediately before the excision and the end of the opera-

[1] Doyen, Internat. Gynec. Cong., Brussels, 1892.

tion. Doyen, independently of us, has also advocated this principle.[1]

This modification of Péan's technique is not the result of an innovation mania with us, but is of absolute, intrinsic value to the operation. Experience has taught that every clamp employed is to a certain extent a hindrance to the operator, and in unskilled hands traction on these instruments may cause hæmorrhage and undesirable laceration. With a number of clamps in use during the operation, the space for fingers and instruments in freeing the internal genitalia is very unpleasantly limited, especially in case of a small narrow vagina. Further, these forceps in place before the organs are resected are more or less an obstacle to the convenient formation of the pedicles, for by their use one gets a variable number of small stalks instead of a large and firm pedicle which could have been had by dispensing with them until everything had been properly liberated. What could well have been brought into one mass, easy of supervision and convenient for traction toward the vagina, is divided up into many parts.

Therefore every clamp applied prior to the freeing of the organs hinders complete extirpation; the areas marked off by the hæmostatic forceps limit the field of the operation. Undeniably Péan and Segond's technique, in which the control of the hæmorrhage plays the chief part, suffices for the removal of the uterus; but it is equally certain that it presents greater difficulties in the execution of the vaginal radical operation. We acknowledge this all the more readily, for, according to our own experiences, there are occasional instances in which, before the adnexa can be resected, nothing else than Péan's method is possible—total extirpation or morcellement with preventive clamping. Segond, feeling that this prophylactic use of the clamps was a hindrance, has emancipated his own method also from the strictly bloodless operation. However, he advanced only half a step, for he still secures the uterine arteries before commencing the excision of the womb. And when Péan and his school recommended the simple removal of the uterus

[1] Landau and Doyen, Twenty-fourth Congress of German Surgeons, 1895.

for all the forms of pelvic suppuration, it would seem that this limitation, with which they were satisfied, was the direct result of their chosen prophylactic method.

We have, on the contrary, dispensed with all primary hæmostasis; our chief aim is to first liberate all the structures involved, bring them down into sight, and form a pedicle. Hæmostasis is the last and the closing act of the operation; with Péan it is the chief care, ever recurring throughout the whole operation. This endeavour on our part causes our method to very materially differ practically from that of the original Péan's operation, in spite of our use of his clamps.

In order to illustrate the development of the method, we may briefly review the chief points in the treatment of diseases of the adnexa as practised in our clinic:

Differential classification of pelvic suppuration; accurate diagnosis, assisted when necessary by exploratory puncture to establish the purulent nature of the so-called parametric indurations; the treatment of each case on its merits, vaginal or abdominal incision; vaginal or abdominal extirpation of diseased appendages, or the vaginal radical operation — the first procedure always when the trouble is unilateral, the latter always in case of bilateral disease. The vaginal radical operation also in *bilateral* non-suppurative affections; as well as for the severest cases, complicated pelvic abscesses, in some instances with the aid of ventral laparotomy. In the technique: introduction of the palpatory enucleation, primary liberation of all the tissues, and pedicle formation, hæmostasis being secondary. Prophylactic hæmostasis in the sense of Péan's operation only as a method of necessity.

CHAPTER V.

THE VAGINAL RADICAL OPERATION IN A BROADER SENSE.

For the vaginal extirpation of myomatous uteri we employ the same principles of technique; but here, of course, among the other manipulations, Péan's morcellement holds the chief

place. As is well known, this operator and Urdy devised the method as early as 1873 for the abdominal extirpation of myomata. Péan employed it for tumours of other organs as well, but especially in vaginal myomo-hysterectomy, vaginal hysterectomy, and hystero-myomectomy.

We have tried this method in a large number of fibroids, some reaching to the umbilicus, and with excellent results. In the last few years we have had equally good results with other methods, namely, the combined abdomino-vaginal operation, lately described by L. Landau, and Doyen's brilliant and astonishingly simple abdominal extirpation. Still, in selecting a method of removing a myomatous uterus, as far as it is a matter of choice, we should always seek first for contra-indication to the vaginal procedure, rather than for indications for laparotomy. We take this stand because in general we prefer every vaginal operation to the abdominal or the combined methods, and naturally with the presumption that a greater number of operations will demonstrate the greater worth of the vaginal procedure.

The chief technical principles involved in the vaginal radical operation for diseases of the appendages, and in vaginal hysterectomy for myoma or cancer of the womb, are all so in accord, and uterine and adnexal disease are so often combined, that we are prompted to include in the term 'vaginal radical operation' all vaginal hysterectomies undertaken for the above-named indications. In the removal of the uterus per vaginam for prolapse, uncontrollable hæmorrhage, carcinoma or myoma, vaginal hysterectomy can, in case of normal appendages, and *should*, if the latter are diseased, take the form of the vaginal radical operation.

So the list of indications is increased; but in spite of their variety, the technique of the operation remains, as a whole, the same, with minor variations and subdivisions.

The following description of the technique is based upon an experience of nearly 500 cases so treated.

PART II.

TECHNIQUE OF THE VAGINAL RADICAL OPERATION.

A.—GENERAL CONSIDERATIONS.

When, for a number of different conditions, the operative procedure required is in all essential points the same, it follows that certain surgical principles of general applicability will recur and be made use of in each individual operation. The opponents of the operation in question have attacked every single point of the method, always with reference to general 'surgical' principles, apparently forgetting that a great many modern views, once accepted as finite surgical dogmas, have nevertheless been changed in the course of time.

On these grounds it seems to us necessary, before passing on to the special description of the technique of the vaginal radical operation, to make some observations which will demonstrate in a general way the main principles of our procedure, and test the value of the objections advanced by its opponents.

CHAPTER I.

OUR OPERATION: THE ENUCLEATING PROCEDURE—THE SO-CALLED CLAMP METHOD—QUALITIES AND ADVANTAGES OF THE CLAMPS.

Nothing has hindered the proper understanding of our vaginal extirpation of the internal genitalia more than the common term 'clamp operation.' Péan's clamp method

did, indeed, suggest the way along which our procedure was developed, but our technique is not that of the clamp operation, and cannot properly be described by this term. The first step in Péan's work of reform consisted in this, that he taught the use of the clamps instead of the ligature as a means of controlling uterine hæmorrhage. Herein lay the difference between his and the other methods of hysterectomy, and this circumstance made his operation the clamp method *par excellence.*

This is the proper designation of those methods of extirpation in which the clamps are employed from necessity—that is, in operating on large immobile uteri which do not respond to any downward traction. But apart from this, our use of the clamps is of a secondary consideration; in fact, our procedure is entirely different from the original Péan's method.

For Péan and his school, throughout the whole operation, the control of the hæmorrhage, the 'preventive hæmostasis' is of chief importance; for us the complete freeing and isolation of all the structures to be extirpated is of chief moment, even to the neglect of the vessels. With Péan the hæmostasis is, with reference to the enucleation, *preventive* or *primary;* with us it is *consecutive*—that is, *secondary.*[1]

Thus, if Péan's operation be designated as the clamp method on account of the chief principle involved, so must our operation with reference to its fundamental principles be called the *extraction*, or, better, the *enucleation* method.

In our operation, after the essential principle has been carried out, *i.e.*, after the organs or tissues have been freed from adhesions, enucleated and pediculated, as far as the

[1] There is a great deal of confusion among the different writers in regard to the names of the various kinds of hæmostasis used in such operations; the terms 'preventive, temporary, provisional,' and 'definite, consecutive,' are employed very inaccurately.

By 'provisional' or 'temporary' is meant any hæmostatic means which is replaced by some other agent, or removed entirely in the course of the operation. The opposite is 'definite.'

That form of hæmostasis, like Péan's, which precedes the enucleation is to be called 'preventive' or 'primary.' When it follows the enucleation, as in our method, it is 'consecutive' or 'secondary.'

hæmostasis alone is concerned, the ligature or clamp may be used at will. But when we say that we choose the clamp instead of the ligature in every case, this preference is based upon advantages far beyond the use of these instruments merely as a hæmostatic means.[1]

Most certainly they shorten the operation; they spare the patient (often weakened by preceding hæmorrhage) the unnecessary loss of blood, and favourably shorten the duration of the anæsthesia. Further, in certain stages of the operation, the clamps rightly placed may be useful as retractors in exposing the field of operation, and offer a good handle for the examination of the pedicles. This latter procedure is unsafe when the ligature is used, because of the possible slipping of the ligature, and resulting hæmorrhage. Moreover, the weight of these instruments draws the stumps down and maintains them in the vagina in a position which not only offers the conditions requisite for extra-peritoneal healing, but directly assists in the process. This point will be discussed later on.

The clamps serve also for drainage, preventing like a glass or rubber tube the primary adhesion of the wounded edges, and form an excellent framework for the absorbent gauze, which, supported by them and protected from compression and adhesion, develops its full power of drainage.

While the drainage of non-inflammatory cases (myomata) is a matter of choice, it is certainly necessary in all inflammatory and suppurative processes, especially where portions of intra- or extra-peritoneal abscesses, fused to the gut or bladder wall, must be left behind. It is also necessary in purulent carcinomata.

For these latter cases an especially important aid to the success of the operation is the crushing and necrotizing effect of the clamps upon the tissue grasped by them.

[1] The only exception to this rule is in hysterectomy for procidentia. When in such cases the operation is indicated, we prefer the ligature to the clamps; after completing the resection of the uterus and superfluous vaginal wall, we close the vaginal vault with a purse-string suture. Where, however, the prolapse is complicated with inflammatory or suppurative processes, (salpingitis, pyosalpinx, pelvic abscess), the clamps must be used instead of the ligature.

Germs lying in the blood and lymph vessels in parts only microscopically affected are annihilated by the pressure. To destroy the adjacent tissues as widely as possible, the ideal method would be to use some other necrosis-producing agent (thermo-cautery) to those parts of the field of operation which cannot be enclosed within the forceps—for instance, upon the posterior bladder wall, or the anterior surface of the rectum ; but, unfortunately, an extensive, even if superficial, cauterization cannot here be made without grave danger to the patient from necrosis of these organs due to multiple thrombosis. Otherwise the thermo-cautery is of no advantage. To burn the ligaments inside the clamps, and then remove these latter, seems inconsistent ; it is better to leave the clamps in place, and let them destroy the tissue by pressure, which they will certainly do for at least their own breadth. On the other hand, when the ligaments are severed by the cautery, and the clamps left in place, the cautery has merely performed the service of any cutting instrument, such as the knife or scissors.

Further, it seems to us quite possible that, in the ligature operation upon a cancerous uterus, the needle in transfixing the ligament may carry germs from diseased into healthy tissue.

As we see, the clamp method is, after all, something more than a special form of hæmostasis ; it possesses besides this other qualities which recommend its use : drainage, extraperitoneal wound-healing, etc. These properties are of such a decided advantage over the ligature method that, even in the cases where it is easy to control the hæmorrhage by ligation, we discard it in favour of the clamps. Although, as before stated, in certain stages of our operation the ligature may be employed in the technique, it must not be inferred that we were contemplating a return to the old and commonly used ligature method. *Our operation is neither the clamp nor the ligature method, but is an enucleation procedure*, a method which proposes the liberation of the internal genitalia in one mass, and *which is concluded by the use of forci-pressure* instead of ligation, which, as far as hæmostasis is concerned, is just as practicable.

In the small number of cases in which the enucleation process is not practicable, the usual ligature method is quite impossible. Here the 'clamp method' is the operation of necessity, solely on account of the hæmostasis, and here it is a quite indispensable factor to the success of the operation. Such are the cases in which the uterus is directly or indirectly fixed and immobilized by its size, by adhesions, or by changes in the adnexa, and the areas in which the hæmorrhage must be controlled can in no way be made mobile. When, in these cases, the old vaginal methods of operation are tried, although some assistance may be derived from auxiliary operations, such as perineal section, sacral and parasacral incision and resection, the procedure is bloody, demands a great deal of time, and is often impracticable. The blood-vessels are high up, and to reach and ligature them is a matter of the greatest difficulty. The most zealous champions of the ligature method are often obliged to employ the clamps in such cases, and leave them on from necessity.

We acknowledge that, in some cases of the above sort, uteri with large myomata, or with bilateral inflammatory changes in the adnexa, may be removed per vaginam by the ligature method, but not without difficulty. But those cases which most of all demand a radical operation are precisely the ones which are in general excluded from the possibility of vaginal removal, unless the advantages offered by the clamp method are made use of. Such are large uteri walled in by inflammatory products, enormous pus-tubes with intra- and extra-peritoneal abscesses, complicated pelvic suppuration; these are cases in which the organs fixed high up in the pelvis can be extirpated by aid of the clamps, with certain control of the hæmorrhage.

Thus, in this category the ligature may be of service in isolated cases, the clamps in all, without exception. *Accordingly, the proper method here lies in the use of the clamps, not the ligature.*

If in this description of the clamp method we have entered somewhat fully into details, we can dispose of the objections of its opponents very briefly, and mainly with regard to two points:

First by the simple reference to our results obtained in a series of nearly 500 operations.

Secondly, it is a striking fact that all the objections have been brought by those who do not practise the method themselves, or, what is still worse, by those who without proper knowledge of the technique, or without a suitable armamentarium, have tried the operation once or a few times, to the injury of their patients.

Secondary hæmorrhage and injury of adjacent organs are certainly not more frequent with the clamp method than with the ligature. The further objections—uncertain control of the hæmorrhage during the operation, danger of embolism from excessive thrombosis, laceration of the ligaments, etc.—can only come from those who are not well acquainted with the method. That some gynæcologists with a limited experience have had a high mortality in their cases, or, as some have said, only fatal cases, with the clamp operation, is a matter which it is difficult for us to explain. But their failures cannot be allowed to put in question the excellent results achieved in a large series of operations by other writers, nor to detract from the value of the method, any more than so much theoretical discussion; for facts are stronger than theories.

CHAPTER II.

NON-CLOSURE OF THE ABDOMINAL CAVITY—MECHANISM OF THE HEALING.

We shall describe in further detail one point in connection with the use of the clamps: not because it might serve those unacquainted with the procedure as a leading argument against the clamp method, but because it forms one of its important and useful features; namely, the closure of the peritoneal cavity. This, in the ligature method, is completed by suturing, for fear of infection of the peritoneum; but in the clamp operation it must be left out.

This is what we consider an especial advantage of the clamps, one that is chiefly brought into play in the operation

for inflammatory purulent or ichorous affections of the uterus and appendages.

Indeed, so little do we regard the non-closure of the peritoneum as a weak point of the clamp method, that we do not shut off the abdominal cavity from the dangerous vagina even in cases where we employ Doyen's ingenious abdominal hystero-myomectomy with the ligature. The favourable and possibly astonishing results of this intentional neglect are due to the fact that the peritoneum closes itself in the most effective manner, and that rapidly and in the best position.

With the ligated inflamed stumps sewed into the wound, resting upon the peritoneum, and remaining in contact with it during the entire process of healing, an ideal extra-peritoneal arrangement is difficult to achieve. With the use of the clamps, however, the healing process takes an entirely different course.

By the weight and traction of the clamps all the stumps, even the uppermost portions in the region of the infundibulo-pelvic ligament, are inverted into the vagina, and the pedicles lie not only extra-peritoneal but intra-vaginal, similar to the disposition of the pedicle after ovariotomy, where the clamp was formerly used, although in a much more reasonable position. This position is a permanent one, for the traction of the clamps during at least twenty-four hours changes the elasticity of the tissue so that the stumps do not retract again into the intra-peritoneal region even when the infundibulo-pelvic ligament is included.

The gauze covering the entire wound surface, and extending beyond the points of the forceps, powerfully excites the rapid formation around it of peritoneal adhesions, and, as it remains there for several days, it further assists the plastic tendency of the peritoneum. The peritoneal sac is thereby rapidly closed, the wound cavity becomes transferred from its original situation into the vagina; hence the new closure of the peritoneum lies in the proper position, *i.e.*, above the level of this self-cleansing wound. When we consider, in addition, the drainage effect of the clamps and gauze, and the fact that the discharges and necrotic products have a natural and safe outlet through the vagina, we see that all

the necessary conditions for the open-wound treatment, which alone is suitable for inflammatory and suppurative processes, are amply provided for, and that the most effective protection against retention and sepsis is secured. By the use of the clamps and the gauze drainage, this self-protection of the peritoneum is so complete that the after-treatment is reduced practically to nil. The vaginal douche with some bland solution, which we employ first on the sixth day, is chiefly for the mechanical removal of shreds of tissue and secretions.

The non-closure of the peritoneal wound offers also a ready means for the recognition of any secondary hæmorrhage which may occur from the stumps, an advantage not to be lightly esteemed. Bleeding at any time after the operation manifests itself at once outwardly, whilst after closing the abdominal cavity, a fatal hæmorrhage, from portions of the stumps which have slipped out of the ligature, may occur in a most insidious manner.

The results achieved in spite of the non-closure of the peritoneum and the negative after-treatment, even with the most extensive suppurative affections, might suggest the thought that we have always had to deal with sterile pus or with non-virulent inflammatory agents. The best answer to this is that a large number of the cases had a septic temperature before or at the time of the operation; several times also those participating in the operation had to bear evidence on their hands of the virulence of the pus. To this is to be added the experience that in some purulent cases where laparotomy had to be combined with the vaginal operation, here and there, in spite of all precautions, abscesses occurred in the abdominal wound. This human inoculation is certainly not less important as a proof of pyogenic virulence than tube-culture or animal inoculation.

While the open treatment ensures an excellent self-protection of the wound against infectious bacteria after the operation, the method limits the danger of infection of the adjacent tissues, especially the peritoneum, *during* the operation, and this without special irrigation or disinfection. For in every part of the operation we are governed by the

principle of non-interference with the peritoneum, which overlies the wound in two broad, loose flaps in front and behind. Purulent and decomposing fluids escape through the vagina at once, and, what is most important, all wound surfaces which might serve for the inoculation or diffusion of pyogenic bacteria are mechanically shut off from the general circulation in a certain and safe manner. Even if a large number of lymph and blood vessels are opened during the extirpation, these points which might be directly inoculated by the septic material present are at once rendered devoid of danger by no other agent than the compression forceps, which grasp and crush the whole breadth of the ligaments. The ligature whose only purpose is to control the hæmorrhage could only have this crushing effect in the very isolated cases in which the whole ligament is tied off in one mass. This protective effect of the clamps on the tissues remains operative long after the forceps are taken off.

The large lymph channels which accompany the uterine arteries in the 'cardinal ligaments' (Kocks), and pass by the side of the cervix, are, together with those in the round ligament and in the upper part of the broad ligament, all grasped and crushed by the clamps. The only part not secured by the forceps is the cellular tissue in front, and in some cases that behind the cervix. From the absence of suppurative or phlegmonous inflammation extending from here behind the peritoneum, or in front into the cavum Retzii, one must conclude that these tissues have but little tendency to the development of secondary infection. Thus, in spite of the presence of virulent bacteria, the technique of our vaginal extirpation offers no opportunity for local or general infection either during or after the operation.

It only remains for us to consider in a few words the anatomical changes occurring in the self-closure of the peritoneum. In this matter we must be guided chiefly by theoretical principles, for we have had no fatal cases that could furnish any definite information on this point. The process of healing consists mainly in the formation of adhesions by omentum and the intestinal serosa round about the gauze, or in the coalescence of the peritoneal flap

loosened from the front of the uterus with the serosa of the rectum.

From the observation of our patients for many years, we maintain that, in spite of the probable frequency of the first method of healing, dangerous, or even unpleasant, intestinal disturbances do not result. Most likely the newly-formed adhesions are soon stretched or separated by the peristaltic motion of the intestines, which are very much less disturbed by the vaginal than by the abdominal operations.

We do not believe in the theory that the closure of the peritoneum takes place through the primary union of the surfaces of the broad ligaments, which are drawn down funnel-wise into the vagina by the clamps. The only portions of these structures which lie in contact are their central parts, clamped and necrotic.

The definite closure of the wound in the vaginal vault beneath the long-since-healed peritoneum is a typical union by secondary intention, favoured by the succulence and thickness of the paracervical tissues.

The fear that the non-closure of the abdomen might allow the intestine to become prolapsed and strangulated, especially during the vomiting after the operation, is answered by the fact that we have observed this form of strangulation in only one case out of all our operations. This was a patient who, on the fourth night after the operation, got up without the nurse knowing it, and walked about the room; the result was intestinal prolapse, obstruction, and death. The method, however, cannot be blamed for this death.

The absence of intestinal prolapse may be explained by the shortness of the mesentery, which allows the gut only a limited excursion towards the pelvic outlet; besides this, the protrusion is hindered by the anterior vaginal wall, which, together with its peritoneal flap, is pushed upward by the gauze beyond the clamp points, forming a smooth and firm protective pad.

CHAPTER III.

MORCELLEMENT.

In a certain number of cases the ligature method is unavailing, and the clamps must be used to bring these cases within the scope of the vaginal operation. So in like manner the principle of dividing up the mass is brought into play as a second effective remedy—*morcellement* in the full sense of the word.

This procedure is employed wherever it is impossible to deliver the structures entire; it must always be done under full visual control. Its purpose and aim is either to diminish the organ by partial dissection until it can be removed through the vagina, or, by cutting away portions of the mass, to make room for its enucleation and extirpation through the space so gained. These morcellating procedures are chiefly auxiliary; they become independent operations only when it is necessary to extirpate the whole organ in this way. So far as a radical operation is concerned, this method is required for the uterus in the first place for fibroids, and in the second place for grave inflammatory or suppurative adnexal tumours, when the uterus is firmly walled in, and for pelvic peritonitis, with fixation of the organ.

To this latter group belong also those conditions in which it is impossible to deliver the uterus as a whole on account of the brittleness and friability of its parenchyma. These are chiefly cases of puerperal subinvolution, complicated pelvic abscesses after labour or abortion, or metritis with severe œdematous or cellular infiltration.

By the aid of morcellement, therefore, three obstacles are overcome: firstly, enlargement of the womb, preventing its delivery through the pelvic outlet; secondly, direct (perimetritis) or indirect (diseases of the adnexa) fixation, which hinders the descent of the organ into the lower plane of the pelvis, and thereby obstructs the access to the upper portion of the uterus and the appendages; thirdly, great sponginess and friability of the uterine tissue, which would otherwise

prevent extirpation. Naturally, the difficulty may be greatly augmented when one has to deal with an enormously large uterus directly or indirectly fixed, or when a combination of softening with fixation is met with.

A matter of great importance in all these procedures is in a certain sense their prophylactic side. They permit of the extirpation of fixed or enlarged uteri, and also of organs in which these conditions are both present at the same time, giving the operation in this way an extension, especially with the clamps, far beyond the limits of the usual Czerny method. They thereby limit, or entirely do away with, the auxiliary operations which supplement the latter method, *i.e.*, the sacral and parasacral methods, Schuchardt's operation, laparotomy, and that hoary antiquity the perineo-vaginal section.

It cannot be otherwise than beneficial to the patient when one avoids further dangerous and mutilative injury to other structures when doing the vaginal extirpation. Technically it is really not clear why one should unnecessarily give such operations more liberty here, in contradistinction to the general effort to avoid neighbouring injuries wherever possible.

Those who like striking expressions may designate the above procedures as 'unsurgical.'

As an aid to morcellement in case of uteri indirectly fixed by serious purulent or hæmorrhagic exudates about the adnexa or encapsulated inside or outside the peritoneum, comes the evacuation of these cysts during the operation through a wide opening in the vagina.

CHAPTER IV.

CLASSIFICATION, MECHANISM AND METHOD OF PERFORMANCE OF THE MORCELLATING OPERATIONS.

We divide these operations on the uterus into two large and distinct groups: Section of the organ, and piecemeal extirpation—'morcellement' in the true sense.

By section we understand the methods in which the womb

is opened in the sagittal line through one or both walls—*i.e.*, partial or complete section. In the latter case it is, of course, divided into two lateral symmetrical halves. By morcellement or piecemeal extirpation we mean the methods by which the organ is dissected and cut away in pieces. The incisions and the resulting masses may show a certain symmetry, or they may be entirely irregular and asymmetrical; accordingly there is to be distinguished a regular and an irregular morcellement.

As above stated, the principle of all these procedures is to make room by freeing or extirpating the obstructing parts, so that the remainder of the organ may be enucleated in one mass, and its pedicle secured. As a rule, these operations are merely auxiliary. They are independent procedures only where, in spite of morcellation, the enucleation of the remaining parts is not possible until the organ has been entirely dissected away; the whole operation is then a continuous morcellement.

A uterus immobilized by its size (myomata) or by perimetritic adhesions or diseased adnexa is broadened out merely by splitting the anterior or posterior wall in the median line; *it is unrolled like a cylinder after a vertical section, and its thickness is materially diminished.*

Sagittal incision of one of the uterine walls is often sufficient, by the resulting flattening of the organ, to render mobile a womb previously fixed by its size, and to enable it to be delivered into the vagina; or, in other cases, the pelvic cavity is made accessible where it was previously closed by the enlarged organ like a cork in the neck of a bottle. The unrolling, which follows the median incision, forms a breach, or rather a canal, through which one or two fingers may be passed over the fundus into the true pelvis, and parametritic adhesions torn away, collections of fluid evacuated, or the adherent appendages loosened. If the fixation is chiefly due to inflammatory products about the tubes and ovaries, which hold the uterus by traction on its sides and upper angles, the incision not only gives more space through the unrolling and flattening of the organ, but it also renders it mobile by lessening the strong tension upon it. The traction right and

left from the median line is correspondingly decreased at every point on the uterus after the wall is opened.

It is evident that the complete median division of the organ must have at least double the benefit of the simple incision of one wall. By this procedure, which comes into play chiefly for the enucleation of fixed and gravely-diseased adnexa, a broad gaping space is formed in the middle as a result of the entire abolition of this traction from the sides.

From these sectional methods those which we designate as piecemeal extirpation differ only in degree, not in principle. They are indicated when it seems impossible to extirpate the organ as a whole with or without the sagittal incision, or when this fact becomes evident during the operation. Very often morcellement, or even the median incision, is of great advantage as a method of choice, since the perineal and vaginal incisions are avoided thereby, and all the structures to be extirpated can be brought into sight one after the other. Morcellement is a necessity when bilateral tubal, ovarian, or other extra- or intra-peritoneal abscesses are present, together with broad, hard, pelvi-peritonitic masses which quite obliterate the pouch of Douglas, and extend solidly to the pelvic floor. In such a case the mere sagittal section would be entirely insufficient, for the right and left halves of the immobilized organ do not retract laterally; they are walled in by these masses and remain in place, an obstacle in the way of reaching the diseased appendages. The solid direct or indirect fixation of the uterus, even when not accompanied by enlargement, often necessitates its extirpation *in situ* by means of morcellement.

Morcellement is further required for uteri which, surrounded by encapsulated abscesses, have become abnormally friable through inflammatory œdema, softening, and cellular infiltration, or in cases where the softness and fragility are due to puerperal subinvolution. In such cases strong traction on the volsellæ leads at once to laceration and hæmorrhages.

Finally, the method of piecemeal extirpation is forced upon us in cases where the womb, previously opened or

halved, cannot pass through the natural obstetrical outlet; for instance, cases of enlargement caused by tumours, more especially fibroids. Myomata reaching to the navel, together with the uterus, may be removed through the vagina by morcellement, with more trouble to the operator than danger to the patient.

In testing the mobility of the uterus, one must not be too easily deceived; sometimes by traction on the portio the organ seems to descend into the vagina, merely because the elastic cervical tissue is put on a stretch and yields somewhat, while the corpus, fixed by its size or by adhesions, remains in place unchanged.

A parallel may well be drawn between the mechanism of piecemeal extirpation and certain obstetrical procedures. In removing a dead child, one would wish to avoid Cæsarean section when it was possible to deliver through the natural passages. One would prefer to deal only with those structures which must be eliminated from the body, avoiding injury to neighbouring tissues, and leaving the parts which remain as intact as possible. The condition in which a dead fœtus passes through the natural outlet is quite immaterial, whether entire, with a perforated skull, or in shreds and pieces, as in embryotomy.

Morcellement, by diminishing the solid tumour mass, accomplishes exactly the same purpose as that achieved by perforation in case of hydrocephalus, or by embryotomy on the dead child in cases of contracted pelvis. The manipulation here occurs only upon those parts which must be sacrificed and eliminated from the body at any price. Æsthetical considerations of the nature and manner of its diminution do not arise; the welfare of the patient is the sole and exclusive care.

It is often astonishing how easily a myoma, whose size absolutely prevents its entering the pelvic canal, may be delivered by this route after excising only a small portion of its mass. But this is readily explained by referring to similar conditions in obstetrics. A conjugata vera, too narrow by 1 centimetre, may render the normal course of labour impossible, while, on the other hand, a corresponding

slight change of the size-relations suffices to make the delivery quite easy *per vias naturales.*

While in obstetrics the piecemeal extirpation, embryotomy, is necessarily an irregular procedure, these methods have been so far developed in the vaginal radical operation that we may distinguish a symmetrical and an asymmetrical morcellement. The one or the other is indicated according to the more or less symmetrical relations present in the individual case. For a non-enlarged uterus situated in the median line one would employ Péan's geometrically regular morcellement; for a symmetrical transverse hypertrophy the V-, Y- and disc-shaped incisions; and in the completely irregular nodular contour the incisions must be made to suit the requirements of the case. Under the asymmetrical methods are included also the enucleation of fibromata by incision of their capsule and the simple resection of such when pedunculated.

In the irregular morcellement, one either cuts away portions of the mass successively, working from the middle and undermining the capsule, or, beginning at the free periphery, the tumour is boldly cut into where most convenient, and larger or smaller wedge-shaped blocks and sections brought away. The shape of the wedges and slices so removed is, of course, always irregular and variable.

In all the methods of morcellement, as in all the vaginal extirpations, the chief aim and principle throughout the whole operation is this: primary enucleation of the diseased organs, and formation of the pedicle. In embryotomy one dissects only as much as is necessary to equalize the space relations—that is, until the remaining portions of the ovum can be delivered in one mass; likewise in the vaginal radical operation the dissection is continued only until the diseased structures can be entirely freed, and a suitable pedicle formed.

Morcellement, as stated, is chiefly an auxiliary operation, and in this sense this valuable procedure comes into use not merely for the vaginal extraction of uterine tumours, but also for intra-ligamentous fibroids and voluminous tumours of the adnexa (ovarian fibromata, etc.).

CHAPTER V.

MORCELLEMENT AND HÆMOSTASIS.

It may be asked, How do we control the hæmorrhage in these dissecting operations? Are there not great difficulties and dangers here? Not at all. On the contrary, we can say that in most of these procedures we are able so far to neglect the hæmostasis during the operation that we can develop with no danger whatever, and to its fullest extent, our principle of primary enucleation and pedunculation of all the structures, with secondary hæmostasis. Hæmorrhage during the operation is controlled solely by the traction and pressure of the fixation forceps.

The anatomical conditions rendering this manœuvre possible are chiefly these: the main arteries supplying the uterus and its appendages, the uterine and spermatic, with their accompanying veins, lie wholly along the sides of the womb. No vessels worth mentioning ramify in the para-uterine tissues either on the front or back of this organ; and, what is most important, those entering the parenchyma undergo a rapid diminution in number and size toward the median line. Thus, the median portion is but sparely supplied, and the sagittal plane is as little vascularized as, for instance, the linea alba abdominalis.

A similar condition of rapidly-diminishing blood-supply is present in the tumours of the uterus; the large arteries and veins ramifying on it from the capsule undergo a rapid diminution toward the centre of the tumour. Consequently, the operator who splits the uterus partly or wholly down the middle line has no hæmorrhage of importance to fear, because he avoids the dangerous lateral portions by working as much as possible in the centre of the tumour. In morcellating the uterus, one need not keep so anxiously in the median line, but may go rather wide laterally, provided that upon the portions enucleated and delivered a constant traction is made sufficient to close the lumina of the smaller vessels by stretching and compression. It is often surprising to see how absolutely bloodlessly one may operate, in spite of the

most extensive dissection of this sort, without any necessity for the primary (preventive) application of the clamps, and assisted merely by the traction and compression of the fixation forceps.

From this point of view, the volsellæ, apart from their use as fixation forceps, assume a very important rôle as hæmostatic instruments; in fact, they are often the only ones used during the whole operation.

On the other hand, when it is absolutely necessary to begin the morcellement in the lateral portions of the organ, where pieces of the uterus extending into the vascular regions must be extirpated, then the traction exerted by the forceps will hardly suffice. Therefore in such cases the hæmostasis must be preventive. These are chiefly cases in which the uterus is fixed by firm direct or indirect adhesions, and, in spite of all efforts, cannot at first be loosened; or in which the fixation of the organ is due to its size, where only by and after the removal of portions extending into the broad ligaments can the remainder be set free. Here preventive hæmostasis is the method of necessity, and it not infrequently so remains until the very end of the operation. When anyone asserts that he has always succeeded in the vaginal extirpation without resorting to primary hæmostasis, it only proves that he has failed to employ the operation in a series of cases which Péan, Segond, and others would have attacked from the vagina.

In all such cases morcellement gives room for further work, but does not allow, at the outset, the uninterrupted progress of the enucleation and pedunculation of the structures; therefore the control of the vessels by the clamps must always precede the resection.

But in all other cases where the method suffices to give room and mobility without cutting into the broad ligaments, and where the upper portions can be successively reached and brought down with the formation of a pedicle, *the hæmostasis is purposely left as the closing act of the operation*, and according to choice the clamp or ligature can be used. So it is in a great majority of the cases where the uterus is split, and also in many morcellements; and, in general, in all piecemeal extirpations where preventive clamping has

been at first employed, and where in the course of the operation it becomes possible to enucleate the remainder of the organ or tumour primarily.

From this it follows that there is no definite correlation between morcellement and clamps, nor between the former and preventive hæmostasis.

In the same sense the following corollary may be deduced in reference to the vaginal morcellation of myomata: As there is no absolute rule determining the form of morcellement, there is also no definite method of hæmostasis, either preventive or consecutive.

CHAPTER VI.

OUR CLASSIFICATION OF THE VAGINAL RADICAL OPERATION ACCORDING TO ITS USES—THE INDICATIONS BASED UPON TOPOGRAPHICAL ANATOMY.

For the description which we are about to give of the special technique of the vaginal radical operation, we distinguish the following groups:

A. Removal of structures without mutilation of the uterus:
   - (*a*) When the uterus is movable.
   - (*b*) When the uterus is fixed.

B. Removal of structures with mutilation of the uterus (Morcellation):
   - (*a*) Splitting the uterus.
     1. Median incision of one wall.
     2. Total median section.
   - (*b*) Morcellement.
     1. Symmetrical.
        - (*α*) With V-, Y- and disc-shaped incisions.
        - (*β*) Bilateral incision, with removal of the intervening horizontal sections.
     2. Irregular.
        - (*α*) When the uterus is of normal size.
        - (*β*) When the uterus is enlarged.

While the operative treatment of the uterus is selected as the basis of this classification, the procedures to be described include and contemplate in every case the removal of the adnexa as well; in fact, the condition of the latter frequently decides the method of the extirpation.

Therefore the above classification is not chosen arbitrarily, but depends on the anatomical conditions of the individual case. The procedure shapes itself mainly according to the local anatomical changes present, and the mechanical circumstances, such as the size and fixation of the uterus and its appendages, taken as a whole.

It is thus immaterial whether the increased size of the organs depends on myoma, pyosalpinx, etc.; or whether the fixation is due to old cicatricial parametritis, to intraperitoneal adhesions, or to tumour of the appendages which wall-in the uterus.

We shall therefore dispense with a classification based on pathological indications, for that would only lead to mere repetition. Such a scheme, where one of the above-named methods would always correspond to a particular pathological condition, is impossible. The reverse is oftener the case, where a single operative procedure is necessary for many anatomical conditions differing in cause and location.

Sometimes, on account of special circumstances, the case may demand transition forms, or combinations of the methods to be described; then the 'mixed' operation becomes necessary—such is, for instance, symmetrical morcellement of the lower uterine segment followed by sagittal section of the remainder of the organ.

Whoever studies the various stages of the extirpation methods to be now described will recognise the justice of the statement that this, the most radical of all methods in its final results, may nevertheless, during its performance, be converted at will into a conservative procedure.

The carrying of it out in practice naturally includes the possibility of the carrying out of all the above-mentioned daughter-operations.

B.—SPECIAL TECHNIQUE.

CHAPTER I.

PREPARATION OF THE PATIENT—THE ANÆSTHETIC, THE ASSISTANTS, ETC.

Preparations.

The preparation of the patient differs in no particular from that usual for major operations. The important points are: Thorough emptying of the bowel by administration of castor-oil, and by rectal irrigation, the latter several hours before the operation; careful cleansing of the external genitals; when possible shaving away the hair a day or so previous to the operation; full bath; local disinfection of the entire field of operation and the adjacent parts: vulva, vagina, cervix, thighs, and lower abdomen.

Although we employ antiseptics (alcohol and perchloride 1 : 1000) for the pre-operative cleansing, we lay the greatest stress upon the mechanical cleansing by the vigorous use of soap and brush. The thorough removal of decomposing ichorous masses of carcinoma before the operation is dangerous on account of the possibility of further implantation of virulent cancer particles. Here the danger of inoculation increases *pari passu* with the effort to be radical.

The patient comes to the operation in a clean long gown and long stockings. Before every operation the bladder is emptied by a catheter as soon as the patient is under the anæsthetic. It may be stated in advance that during or after the operation no antiseptics whatever come in contact with the field of operation or the wound. Especially do we emphasize the point that, as a routine principle, all irrigation during the operation, even with sterilized water, is dispensed with. Even when the field of operation is soiled with stinking ichorous pus (pyosalpinx, pyometra), we do not irrigate; the infectious material is simply wiped away with dry sterilized gauze or sponges.

Anæsthesia.

For the last five years we have used nothing but ether for the narcosis, and only in very exceptional cases do we substitute chloroform for it. These exceptions are cases of nephritis and catarrhal affections of the respiratory organs, although here even the use of chloroform does not entirely obviate some important drawbacks. In over 2,000 anæsthesias in our clinic, ether has given such good results that, apart from these exceptions, we regard the use of chloroform as a retrograde step. Among our patients we have scarcely ever observed a really injurious effect of the ether upon either life or health, even if we include the fatal cases, where it would be very convenient to ascribe the cause of death to the effects of the anæsthetic. Moreover, since ether affects the heart the least of all the anæsthetics, its value is self-evident, especially for those patients, by no means few, with myoma or carcinoma, who are weakened by losses of blood, and whose anæmic dyscrasia may have already led to fatty changes in the heart muscle.

It is also to be noted that it is not only a question of the chemical purity of the ether or of the kind of mask used, but also of a rational and sensible technique. It does not do to suffocate a patient as rapidly as possible, and render her unconscious from carbonic acid intoxication; much rather should a quiet sleep be slowly produced, and the state of unconsciousness be maintained by giving as little ether as possible. Here, exactly as with chloroform, one should administer just as little as may be necessary to keep the narcosis going, not forgetting meanwhile that even when anæsthetized a person cannot live without oxygen. It follows, therefore, that, after the patient is once asleep, the anæsthetist should remove the mask from the face as often and for as long a time as possible.

The saliva that collects is most effectively removed by turning the patient's head to one side, and carefully sponging out the mouth, in this way getting rid of one of the causal agents of aspiration-bronchitis and pneumonia.

Operating Table.

This may be of any desired form or kind, but experience has shown that the most serviceable is one that combines the following advantages: First, the possibility of raising its bed to any height; second, a rapid but not jerky transition to Trendelenberg's position, and its reverse (low pelvic position); and third, the convenient changing from the lithotomy to the ordinary laparotomy position, and *vice versâ*. A table that combines these principles has been constructed by



Fig. 1.—Operating Table.

L. Landau and Dr. Vogel. The undertaking of a grave vaginal operation without some such table is all the less justifiable because everyone who commences such an operation must be prepared to finish it with a laparotomy, when necessary, to carry out the principle of radical extirpation. We present here only the illustration of our table (Fig. 1); a detailed description was published some time ago.[1]

[1] Vogel, 'Landau-Vogel Operationstisch,' 'Berl. Klinische Woch.,' No. 16, 1895.

Position of the Patient—The Operator's Position.

The operator may stand or sit, according to his convenience. The patient lies in the sacro-dorsal position, and, in case the operator chooses to sit, may be brought into the Sims abdomino-lateral position (Péan). In this the patient lies on the left side, the right thigh is drawn up toward the breast, the left leg is extended; the table is on a level with the operator's breast.

With the patient in the sacro-dorsal position, the operator, according to the number of his assistants, may allow the legs, abducted and slightly flexed at knee and hip, to rest in the leg-holders (see Fig. 1), or the thighs may be strongly flexed on the abdomen, and held by the assistants, or by a crutch, thus bringing the patient into the typical lithotomy position. The operator himself sits or stands between the patient's thighs, naturally at a height corresponding to the field of operation.

In every position of the patient there are two points to be attended to: first, that the head be not propped against the chest, which would disturb the respiration and the narcosis; and second, that at any moment during the operation it shall be possible to change the position to a certain degree of pelvic elevation, easily and without disorder. The above-mentioned table seems especially capable of fulfilling this latter condition.

There can be no general rule or direction laid down for the placing of the operator or patient so that certain indications shall always correspond to certain positions. All positions are possible, and all are serviceable; each has its own advantages and disadvantages.

We have tried all possible positions, and have found the sacro-dorsal to be the most convenient, the operator sitting between the patient's thighs.

Number and Places of the Assistants—Leg-straps.

As someone has said, in every major operation two assistants are better than three, one is better than two, and none at all is still better. Certainly, he who can rely entirely

upon his own efficiency is to be envied, but in the vaginal operations to be described this is not possible; one assistant at least is always necessary. The number of assistants is governed by the position of the patient; thus, for instance, the operator (Péan) employing the abdomino-lateral position needs two assistants, and strong ones, solely to maintain the patient in this position undisturbed. Likewise, everyone who operates in the dorso-sacral position must have two assistants if he dispenses with the leg-straps. By trusting the patient's legs to this latter, one can get along with but one assistant, handling the instruments one's self (Doyen).

For our part, we use the dorso-sacral position, work sitting, and, as a rule, do not use the leg-straps; in addition to the two assistants holding the patient's knees, we have a third who sits at the left. The assistants standing at the right and left, and facing the operator, have each to support the sharply-flexed leg of the patient, so that with the corresponding elbow the thigh is held in flexion, and the leg rests across his back. Naturally, the assistants having this task must not regard the patient's thighs as a welcome rest for their weary arms. Thrombosis of the femoral vein may be the deplorable result of such thoughtlessness, and even with the use of the mechanical leg-supports, such a result can be laid to the assistant's account rather than to the ether. One must also bear in mind that an unreasonably strong flexion of the thigh against the abdomen disturbs the breathing and the narcosis.

To the assistant standing at the operator's right falls the especial duty of marking off the limits of the field of operation with the retractor, and of holding back the vaginal wall, together with the paracervical tissue, as these are gradually separated from the uterus, so protecting the bladder and ureters with his instrument. It also devolves on him, according to the operator's direction, to retract the left side of the vagina, and to hold the instruments (claw forceps and clamps) applied to the left half of the uterus and left adnexa. In the same way the assistant at the left must retract the right side of the vagina, and take care of the instruments applied to the corresponding half of the internal genitalia.

The third assistant, who sits at the operator's left, depresses the posterior vaginal wall strongly downward and backward with a flat speculum, and, when necessary, takes charge of the claw forceps, which are fastened on the uterus and tissues to be extirpated. Besides these we need, of course, an anæsthetist, and generally have a nurse to hand us the instruments.

The large number of assistants need not frighten the aseptic enthusiast, for the assistants' rôles are wholly non-active. They do not touch the wound with their fingers in any way, have nothing but the instruments to handle, and have chiefly the duty of exposing and retracting the field of operation.

CHAPTER II.

ARMAMENTARIUM: INSTRUMENTS AND DRESSINGS.

One must not be sparing in the number of his instruments. In many cases, it is true, only a few are required, but at the start one can never tell but that in the course of the operation a great many will be necessary, hence a larger number should always be in readiness.

In the operation under discussion, all the instruments used by us, without exception, are made of steel, hard soldered and nickel-plated. They are easily and thoroughly sterilized —naturally after a preceding mechanical cleansing—by half an hour's boiling in a 1 per cent. soda solution, and during the operation they lie in the same fluid.

Out of the great number of models devised by various operators, we have selected a relatively small number as being always useful (Figs. 3-16).

1. Retractors or Écarteurs.

For the posterior vaginal wall we employ a simple perineal retractor with a narrow or broad, long or short blade, according to the size and elasticity of the vagina and mobility of the uterus. We prefer the short, slightly con-

cave blade (Fig. 3 *b*), which is only 5 cm. long and 4 cm. broad. Besides this, one other speculum of the same shape, 8 cm. long and 4 cm. broad (Fig. 3 *a*).

For the lateral and anterior vaginal walls we use the form of retractor seen in Figs. 4 *a*, 4 *b*; two of these have a blade 10 cm. long, and two 12 cm.; all are 2¾ cm. wide. They are easily introduced as far as the large pelvis and abdominal cavity. The one applied to the anterior vaginal wall serves not only as a retractor, but also as an elevator and raspatory for the soft parts concerned.

The action of the retractors is chiefly one of leverage; the symphysis and horizontal and descending rami of the pubes and the ascending rami of the ischium form a temporary fulcrum for this two-armed lever.

The nickel-plating of the blades increases their light-reflecting power.

In addition to their chief use in exposing the field of operation, all these retractors have the important function of protecting the adjacent organs—bladder, ureters, and bowel.

The short lateral retractors, Péan's long right-angled écarteurs, and Segond's curved écarteurs are certainly very handy, but are all amply replaced by the instruments just described.

Auvard's weighted speculum is as inconvenient as it is useless; only too frequently it bores into the posterior vaginal wall, making deep lacerations which bleed profusely.

It must be remembered that the position of the retractors has always to correspond to the position of the organs, and has therefore to be changed from time to time during the operation. Thus, the number, place, and kinds of specula vary constantly, and the retracting surfaces of the instruments will be of correspondingly greater or smaller extent.

In simple cases of mobile non-enlarged uteri, the use of specula is quite limited; often two short retractors are quite sufficient.

2. Fixation Instruments (Volsellæ).

(*a*) A serviceable condition of the claw forceps used for fixation is absolutely necessary to the safe execution of every

radical operation, for in addition to grasping and holding the tissues, they have the still more important task of controlling the hæmorrhage by traction and pressure.

VAGINAL RADICAL OPERATION APPLIANCES.

FIGS. 3 *a*, 3 *b*, 4 *a*, 4 *b*.—Vaginal Retractors.
FIG. 9.—Ovary Forceps (Doyen).
FIG. 15.—Sickle-shaped Knife, with Respiratory Handle (Hoenecke).
FIGS. 5, 7 *a*, 7 *b*, 7 *c*.—Volsellæ.

In well-made volsellæ the teeth stand perpendicular, or at an acute angle to the jaws (Figs. 5, 6).

We use four- and six-toothed volsellæ of correspondingly increasing strength, from 0·6 to 1·4 cm. broad at the end.

Figs. 7, *a*, *b*, *c*, show the natural size of the ends.

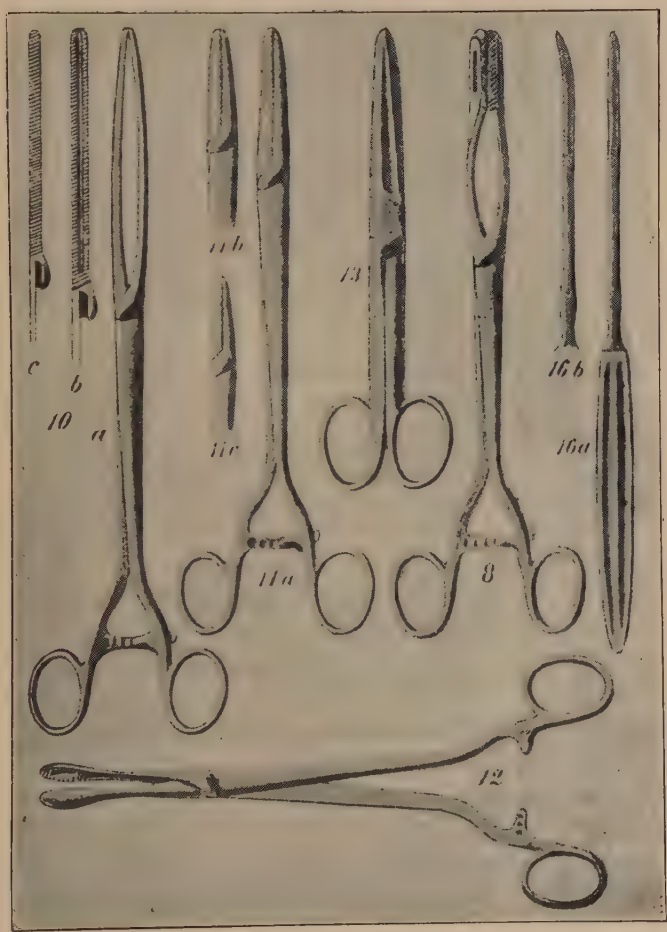

VAGINAL RADICAL OPERATION APPLIANCES.

FIGS. 10*a*, 10*b*, 10*c*, 11*a*, 11*b*, 11*c*.—Broad Ligament Clamp (Doyen, Péan, Segond).

FIGS. 8, 12.—Serrated Forceps for seizing the Uterus in Morcellation (Segond and Doyen).

FIGS. 16*a*, 16*b*.—Knife with Hollowed Blade, for Morcellement (Landau).

We have, at least, eight of the small and four of the large in readiness at each operation.

(*b*) *Fenestrated Forceps.*

(*a*) *With Teeth.*—Two or three of Segond's pattern (Fig. 8), whose especial use is in grasping portions of fibroid tumour.

Nélaton's fenestrated forceps may also be used for the same purpose.

(*β*) *Without Teeth.*—Four of Doyen's pattern, similar to Collin's tongue forceps (Fig. 9). Length 17 cm., but shorter ones may be used also. They are chiefly used in delivering the adnexa. They are somewhat on the principle of the obstetrical forceps; they clasp with a broad surface, and, as they are not toothed, will not lacerate even the softest tissue. Heavier and longer instruments of this sort (length 21 cm.), which we have occasionally tried, are not necessary.

3. Clamps.

At present we use in the vaginal radical operation only straight clamps without the pelvic curve, and prefer in general the pattern with short clamping surface (4 cm.).

If one wishes to follow Doyen's precedent, and inclose the whole width of the broad ligament in the grasp of a single clamp without dividing it first into narrower sections, he must employ the Doyen spring forceps, in order that the whole clamping surface may exert a uniform pressure.

For every operation we have the following ready, sterilized:

(*a*) 2 long Doyen's spring clamps, with the blades grooved in the middle, the edges serrated; length, 27 cm.; blades, 10 cm. (Figs. 10, *a*, *b*). 2 of the same length, but lighter, blades serrated (Fig. 10 *c*). Doyen puts these on inside the heavy clamp for security.

(*b*) 4 of Péan's pattern, with long serrated blades; length, 24 cm.; blades, 6 cm. (Fig. 11 *a*).

(*c*) 6 of Péan's pattern, medium length, serrated blades; length, 24 cm.; blades, 4½ cm. (Fig. 11 *b*).

(*d*) 6 of Segond's pattern, with short serrated blades; length, 24 cm.; blades, 3 cm. (Fig. 11 *c*).

(*e*) 6 very light hæmostatic forceps for seizing isolated vessels, or for clamping vaginal and peritoneal wound edges (Fig. 12).

T-shaped forceps for this purpose have no special advantage.

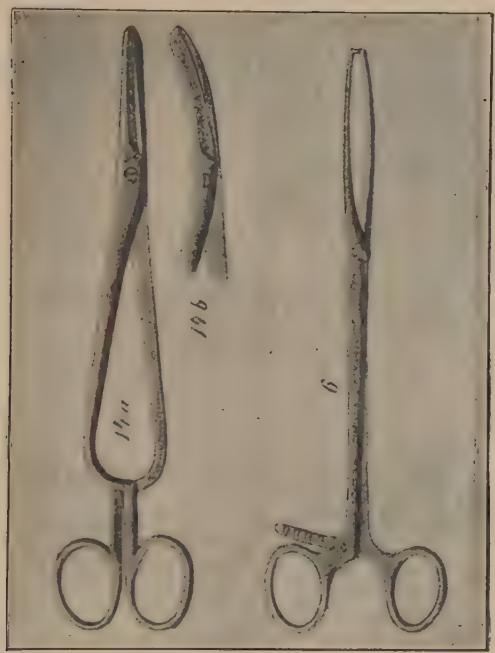

VAGINAL RADICAL OPERATION APPLIANCES.

FIGS. 14*a*, 14*b*.—Long Scissors (straight and curved) for dividing the Uterus in Hysterectomy (Landau).
FIG. 6.—Slender-toothed Clamp Forceps (Doyen).

It is advisable to choose light clamps, in order not to unnecessarily increase the weight of the instruments lying in the vagina.

They must be of excellent quality, and must lock and hold securely, otherwise there is danger of their slipping off or springing open. This presupposes good material and faultless work.[1]

[1] Our instruments, furnished by Chr. Schmidt, Berlin, answer fully to the above requirements, especially the newer models which he has executed for us.

The above list of clamps represents, according to our experience, the minimum number to have in readiness for a vaginal radical operation, although, of course, we cannot designate any certain number as being absolutely requisite. Often a much smaller number will suffice, but, on the other hand, unforeseen difficulties may render a still greater quantity necessary. Nothing can be more harmful to the success of the operation or to the welfare of the patient than an incomplete armamentarium.

4. Cutting Instruments.

(*a*) *Scissors:*

One strong, heavy, and straight pair, with blunt points; length, 17 cm.; cutting surface, 7 cm. (Fig. 13).

One long straight pair, 24 cm. (Fig. 14 *a*).

One same length, curved on the flat (Fig. 14 *b*); cutting surface of each 5 cm.

As these long instruments are intended for deep work, it is better not to have the two latter kinds sharp-pointed.

Scissors with a double curve are unnecessary.

(*b*) *Scalpels:*

(*α*) For the circular incision of the portio, if, instead of the scissors, as used by Doyen and ourselves, the operator prefers the knife.

Brennecke's Knife: This has a secure blade set in a wooden handle, which, if it is heavy enough, can be very conveniently used as an elevator or raspatory (Fig. 15).

(*β*) *For morcellation:*

One straight knife, 23 cm. long, with a 5 cm. blade (Fig. 16 *a*).

One curved on the flat with same length of handle and blade.

5. An Ordinary Uterine Sound.

6. A Female Catheter.

7. Sponge and Drainage Material.

Pledgets of sterilized gauze for sponging away pus and blood.

Mounted sponges for the same purpose.

Preparation of the Sponges.—Soften for a quarter of an hour in hot water; place for two hours in hydrochloric acid solution 1 : 1000; rinse quarter of an hour in sterilized water; macerate for twelve hours in soap and hot water; rinse in sterilized water, and preserve in 5 per cent. carbolic acid solution.

Sterilized gauze strips, 6 cm. wide, 75 cm. long.

In the change from antisepsis to asepsis we have entirely given up iodoform gauze.

Besides the instruments, several basins are needed for disinfection of the hands, alcohol, perchloride solution 1 : 1000, soap, brushes, etc.

One must be prepared to finish with a laparotomy if necessary, in order to complete the radical procedure in case of a technically difficult vaginal operation. Therefore it is advisable to have the necessary laparotomy instruments at hand, needle for abdominal suture, silk, catgut, silver wire, small forceps, etc.

When the operator so desires, the thermo-cautery may be held in readiness for circular incision of the portio, for other incisions, or for cauterizing cancerous surfaces (Jacobs).

For exposing the uterus and adnexa, one may use Simon's lateral retractors, or long or short right-angled retractors. A straight grooved director may be employed as a guide in splitting the uterus, or instead of the straight clamps we may choose those with a pelvic curve. All this is, of course, subject to the operator's individual preference.

The short bistouries, the long surgical forceps, bullet forceps for fixing the portio, forceps with gilded rings or otherwise specially marked as sponge-holders—these, and others which figure in various instrument lists, we consider quite superfluous.

So, also, the long curved knives with various blades, for right and left incision, can be spared.

CHAPTER III.

TECHNIQUE OF THE VARIOUS FORMS OF THE OPERATION—REMOVAL OF THE APPENDAGES AND MOBILE UTERUS WITHOUT MORCELLEMENT.

THIS method of operation is applicable when we have to deal with mobile uteri which are not greatly enlarged, and which admit of downward traction; in its scope it corresponds to the original ligature method in general use. It is therefore indicated in localized carcinoma or sarcoma of the cervix or corpus uteri, and in myomata up to the size of a man's fist, when these cannot be enucleated alone; in cases of bilateral suppuration of the tubes and ovaries when the tubal disease is chiefly lateral, and does not interfere with the mobility of the womb, and hence in bilateral ovarian abscess and in pyosalpinges whose proximal portions are relatively free; finally, in certain cases of true ovarian tumours of both sides, when not too large.

For convenience of description, we divide the operation into successive stages. In this description it will be necessary to discuss incidentally a number of points, such as the situation of the bladder and ureters, the method of applying the clamps, etc., which are of equal importance in relation to each of the methods to be taken up later. They will therefore be noted in this section as opportunity offers.

FIRST STAGE: EXPOSING AND FIXING THE PORTIO.

This includes the introduction of the short broad retractors along the anterior and lateral walls, bringing the portio into view, and fixation of the same with four-claw forceps (volsellæ), one applied to the middle of the anterior lip close to the external os, one at each side in the posterior lip equidistant from the centre. These volsellæ may be pushed well up into the cervical canal without fear of endangering neighbouring structures.

With the volsellæ so applied, the uterus responds readily to traction, if it is at all movable, often coming quite into

the vulva. The two volsellæ on the posterior lip remain in place until the end of the operation merely as a convenient topographical landmark; but in certain cases they are very useful in drawing the portio to one side or the other, in order to bring the broad ligaments within reach. For the same reason we do not remove the volsella from the anterior lip unless the womb is to be opened along its front wall, as occurs in other methods.

Fig. 17.—Fixing the Portio Vaginalis.

Many operators apply the volsellæ in a different way; some place a forceps upon each lip, and, in order to prevent their interfering with each other, apply the anterior a little to the right, the posterior slightly to the left of the median line (Fig. 17). Others seize each lateral commissure with a volsella. Naturally, there is no difficulty in fixing the forceps

on an intact portio; but when ulcerating new growths are present it is different. Here that portion of the lower uterine segment which is to be seized must be first prepared; the soft and friable tissue must be removed by means of scissors, curette, or cautery until the forceps can find a firm hold on the underlying sound muscular tissue.

The fact that injuries to the structures not extirpated (vagina) may become dangerous through inoculation makes it advisable to use great care in preparing the portio when this becomes necessary. In order to avoid a septic or purulent infection, we never subject a cancerous cervix to a 'cleansing process.' Contrary to the practice of some surgeons, we do not remove the tumour a day or so before the hysterectomy by a special operation, for to do so seems to us to be attended with nothing but harm, useless anxiety for the patient, and a repetition of the anæsthesia; hence we always operate at one sitting.

In cancer, on account of its manifold forms, there is no question of symmetrical application of the forceps, and it is at first sufficient to procure a firm hold, which may serve as a point of leverage, and a starting-place for further manipulations. It is especially desirable to hook firmly into the posterior lip, or, when this is destroyed by cancer, into the posterior uterine wall, and here one can go far up into the cervical canal, for the neighbouring organs are out of the way of danger. The same principle holds good, as previously mentioned, in case of an earlier cervix amputation, or in senile atrophy of the portio, viz., to always begin by securing a firm hold of the posterior lip when possible.

In pyometra or in malignant tumours of the corpus uteri, in order to prevent the oozing out of infectious material, one may use the device of catching up and fastening both lips together with a volsella, in this way closing the cervical canal and external os during the operation.

Finally, some operators, for fear of the risk of infection from an inflamed endometrium, make it a rule to precede every hysterectomy with a curetting. We mention this merely for the sake of completeness; it needs no comment.

Second Stage: Circular Incision of the Portio—Various Incisions—Exploratory Incision.

In normal conditions we incise the portio by means of a straight scissors, giving the wound an oval or elliptic form (Fig. 18). Beginning in front above, and as close as possible to the os externum, the incision is carried along laterally exactly in the line of the gaping wound in the mucous membrane, and at the same distance from the os. The portio is pulled upwards and forwards by the forceps, and the circle is completed by an incision which opens the posterior vaginal vault, or at least extends farther from the os toward the cul-de-sac than the anterior incision does. The rule is to direct the cutting instrument always perpendicularly against the uterine parenchyma, severing the fascicles of tissue in this favourable direction, as they are made tense. By keeping the upper and lateral portion of the incision close above the os, the bladder and ureters are protected without any preliminary exploration by the catheter or by vesical injection. Posteriorly the reverse is the case, and the incision is carried higher up, because here one prepares the way to reach the posterior reflection of the peritoneum in the following stage rapidly, without endangering neighbouring organs, and without getting confused in the different layers of the peri-rectal connective tissue. This incision not infrequently opens Douglas' cul-de-sac, and thereby the peritoneum, at once. However, it should not be unnecessarily overdone; when the wound heals after a too extravagant excision, the vagina may be so narrowed and shortened as to render coitus difficult.

Naturally, the outline of the first incision cannot be regular in cases where the portio is brittle or eroded by cancer; where the vagina is also involved in the malignant process; where mutilating operations have previously been performed on the cervix; or where physiological atrophy of the cervix coexists with atresia of the vault. Here, as in the application of the volsellæ, it depends on the anatomical relation present.

For carrying the incision through macroscopically sound

tissue in the presence of malignant new growths, it is relatively more favourable when the cancer has extended on to the posterior wall, for then the circular incision can be begun close to the introitus vaginæ.

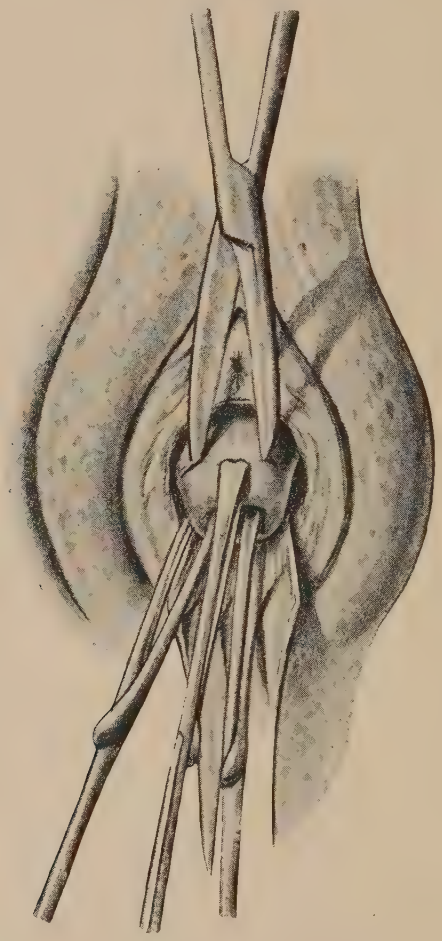

FIG. 18. — COMMENCEMENT OF THE CIRCULAR INCISION ON THE ANTERIOR SURFACE OF THE CERVIX, THE NECK BEING DRAWN OUT OF THE VULVA WITH VOLSELLÆ.

The incision may be made with the scalpel, scissors, or thermo-cautery. At present we use, by preference, the scissors. The 'advantages' ascribed to the use of the

cautery—lessened hæmorrhage, illumination of the field of operation, and delay in the closure of the wound—will scarcely be missed when one uses the scissors or knife.

The bleeding from the first incision is so slight that even the temporary application of one or two small compression forceps is exceptional.

We have already discussed the questionable advantages of the cautery in producing necrosis (p. 38).

The oval form produced by carrying the posterior incision high into the vaginal vault gives a much larger opening than the circular incision, which is equally distant from the os at every point; and one thereby avoids making bleeding lacerations of the vagina during the enucleation of large organs, or in the freeing of their upper portions.

Segond has successfully modified this incision, carrying a lateral cut from each side of the oval for a distance of 2 cm. along and parallel to the base of the broad ligament. The otherwise closed incision now results in the formation of two flaps, an anterior and posterior, similar to those of a limb amputation.

By this means Segond secures two advantages: First, the field of operation in front of the uterus is enlarged to its greatest extent; and second, the ureters are protected in the most rational way from injury by the clamps, which he usually applies to the uterine arteries primarily. For, as will be shortly explained, this point depends solely upon the extensive and careful separation of the bladder, which includes the freeing of the ureters.

As a matter of fact, Paul Segond in 400 vaginal operations for cancer, fibroids, or pelvic suppuration, did not once injure the ureters. We also have used his incision with decided advantage in difficult cases where the space was limited.

For the purpose of the more convenient separation of the bladder, we have abandoned the incision previously used by us, although the bladder and ureters were in no case injured. To protect the vessels below and at the sides of the uterus, and in the arch of the vagina, we formerly left a bridge of mucous membrane intact, right and left from the com-

missure of the lips of the cervix, breaking the continuity of the oval at each side. These were first incised only after the vessels were clamped. Lately this incision has been recommended by Condamin[1], based upon the investigation of the anatomy and distribution of the vessels about the cervix (the arteria utero-vaginalis recurrens).

As a matter of fact, we still in many cases make the first incision, anterior or posterior, only for a certain distance—that is, when we wish to make sure of the indication for a vaginal extirpation, by means of exploratory incision and direct palpation. *This vaginal exploratory incision* in the anterior or posterior cul-de-sac is employed in exceptional cases for diagnosis of inflammatory processes, and much oftener to decide whether or not they are bilateral. In cases of unilocular cystic processes (hæmatocele, retro-uterine abscess, etc.), the exploratory incision is at the same time the curative operation. We find the exploratory incision necessary only in exceptional cases, because, as stated, by proper observation of the patient, careful examination, and the use of other diagnostic measures (rectal examination, exploratory puncture), the diagnosis and indication can generally be sharply defined without it. In suspected malignant new growth of the appendages, of peritoneal tuberculosis, or of congenital malformation of the internal sexual organs, we generally prefer an exploratory incision through the abdominal wall. The eye is here a valuable supplement to the finger.

Thus, for instance, after opening the belly, the sight of nodules upon the underlying intestinal serosa warns the operator at once against further useless manipulation (peritoneal tuberculosis, disseminated carcinoma). If after the ventral incision one wishes to do a radical operation on account of a malignant tumour so found, the eye offers a security of operating through healthy tissues, even when the operation is to be wholly vaginal, neglecting the primary exploratory abdominal opening.

Whether in a given case the vaginal exploratory incision should be made in the anterior or in the posterior cul-de-sac,

[1] Condamin, 'Lyon Médical,' No. 26, June, 1895.

depends mainly upon the situation of the structures to be examined. Therefore we cannot state that the one or the other incision is the one to be used in every case.

Many operators prefer a longitudinal incision in the anterior vaginal wall, as being the most satisfactory for exploration. If it shows an extirpation of the uterus to be necessary, the oval or circular cut about the portio is at once added. We can hardly recommend this plan, because everything that can be palpated can be reached from the transverse incision in the anterior or posterior vaginal vault; and because in hysterectomy after the longitudinal incision the opening must be partly closed again, for the hole in the vagina is otherwise of alarming extent. As a general rule, the sagittal incision in the vagina is unnecessary for exploratory purposes.

Besides this, when this method is used, the bladder must be separated, not only from the uterus, but from the anterior vaginal wall as well, whereas in cutting transversely across the portio in front the bladder and anterior vaginal wall retract in one piece. In the one, the bladder must be loosened from two sides; in the other, from one side only, and by one act.

Apart from its employment as an exploratory measure, however, the longitudinal incision offers at times certain advantages in vaginal hysterectomy. Occasionally, in order to provide for the escape of the secretions through an apparently too narrow vaginal aperture, it may be necessary to enlarge this somewhat by splitting the anterior or posterior vaginal wall down the middle. And, further, it must be borne in mind that in other vaginal operations a longitudinal incision reaching quite to the urethral orifice may be of great service, as, for instance, in the extirpation of small isolated fibroids in vaginal hystero-myomotomy (Doyen), or in colporrhaphy, where one starts from the median longitudinal incision and conveniently dissects and excises two symmetrical lateral flaps. From this it is evident that the longitudinal incision is serviceable in certain cases of vaginal hysterectomy, where at the same time it is necessary to resect a portion of the superabundant vaginal wall. Such

are cases in which the uterus requires removal on account of prolapse of uterus and vagina, or in which vaginal hysterectomy is performed for myoma, double pyosalpinx, etc., and a marked hypertrophy of the vaginal tissues requires to be remedied at the same time.

Finally, one may be compelled to proceed with the extirpation of the womb after beginning with the longitudinal incision for the purpose of hystero-myomotomy, and finding to one's surprise bilateral disease of the adnexa, or grave changes in the uterus itself, calling for a radical operation. Here the usual oval incision must be joined to the sagittal cut, and after the operation is finished the latter must be sutured again. Or, to stick to the clamps, one may narrow the too-broad opening by bringing the edges of the linear wound together by applying light clamps thereto.

That the first incision is in no way prejudicial to the radical operation is evident. The objection that the vaginal operations are, as a rule, more mutilating than the abdominal does not apply at all to the incisions with which the operation is begun, since this latter may be brought to a close directly afterwards if desired. It seems to be forgotten that the vaginal incision has become the initial stage of special and systematic conservative methods of extirpation, which are older than the methodical hysterectomy.

Atlee (1859), Battey (1869), T. Gaillard Thomas (1870), R. Davis (1872), J. T. Gilmore (1873), E. Clifton Wing (1876), Goodell (1876), and others, removed ovarian tumours, tubal pregnancy, unilateral pus-tubes, etc., through the transverse or longitudinal posterior incision, sparing the uterus and the healthy adnexa.[1]

Now that this operation is being recommended and practised under the modern names of colpotomy, vaginal cœliotomy, vaginal laparotomy, etc., these authors deserve at least the credit of having refuted the objection to the vaginal operation—that after it is once begun there is no turning back.

[1] Armand Bonnecaze, Paris, 1889, Inaugural Dissertation.

Third Stage: Freeing the Uterus from the Pericervical Tissue—The Anatomical Relations of the Bladder and Ureters to the Genital Organs.

The separation of the uterus from the pericervical tissue, through the oval incision, is performed either by cutting with the knife or scissors, or by blunt dissection with the finger, or raspatory, using the scalpel handle for this purpose. As a rule, we begin posteriorly, pushing the loose perirectal cellular tissue away from the cervix,[1] when the primary incision has not already opened the posterior pouch of Douglas, giving free entry into the abdomen. Otherwise it is necessary to bore through a variable depth of retrocervical tissue before reaching the posterior fold of peritoneum; the opening of the peritoneal cavity is frequently completed at the same time. In the uncomplicated cases now under consideration, an injury of the intestine is impossible.

At other times the peritoneum recedes; then we do not spend much time in the attempt to get through at this point, but begin at once in front and at the sides of the cervix. The bladder is pushed well up out of its loose connective-tissue bed, as thoroughly and carefully at each side as in the middle.

In freeing the uterus, the separation of the connective tissue about the cervix is combined with a gradually-increasing traction downwards, by means of the volsellæ applied to the portio. If one works in the proper strata, *i.e.*, behind in the loose perirectal cellular tissue, and in front in the yielding, easily-separable layer connecting the bladder and cervix, the loosening of the uterine neck from bladder and rectum occurs in these cases almost of its own accord, aided merely by the downward traction. Small resisting bands are encountered in the perivaginal tissue,

[1] Other operators besides ourselves have observed a peculiar reflex moaning which occurs during the loosening of the perirectal tissue, even in the deepest narcosis; at times also during the denudation of the bladder.

connecting the vaginal mucous membrane with the parenchyma of the uterus; they are simply to be cut through with the scissors. At times small muscular bundles are also found here, passing from the superficial muscular layer of the uterus to anastomose with the longitudinal bands on the posterior surface of the bladder. As Luschka has demonstrated, they leave the uterus in the region of the internal os; some may be traced as far as the urethro-vaginal septum.

The vagina so loosened, together with its submucosa, is rolled upwards by the lifting movements of finger and retractor. The retractor serves in front especially to protect the bladder and ureters, and also as an active aid to the finger and raspatory in the process of separation.

One works here always against the uterus, exactly as in raising the periosteum from a bone. In all these manipulations, especially where the space is limited, the removal of the retractors or écarteurs partly or wholly from the vagina from time to time is often a great help during the liberation of the cervix. In this way the operator's finger is not unnecessarily hindered by the instruments; and by lifting, depressing, or turning the forceps on the cervix one may correspondingly enlarge the space in which he is working.

There is no hæmorrhage during the separation of the cervix if the dissection is made as much as possible bluntly, and if, in loosening the bladder, one does not get too deep into the lateral tissues (arteria uterina). In front, on the bladder, no vessels worth mentioning are divided, and there are no important anastomoses between the vesical and uterine vessels. A possible parenchymatous oozing from the vascular layer of the perirectal tissue may always be safely neglected until the extirpation of the organs has been completed, because the pressure of the uterus as it is drawn down controls the bleeding, just as a tampon would.

Injury to the bladder and ureters will be avoided if the rules above given for the incision are observed—that is, to keep as close as possible to the external os in front and at the sides. In like manner, during the liberation of the cervix, these structures must be so removed from the field of operation that during the succeeding stages

(clamping and resection), they remain protected from every injury, and do not really come into view again. With this task fulfilled, one of the most dangerous reefs in the vaginal hysterectomy has been successfully navigated.

The significance of the incisions recommended, and the above-described manner of freeing the cervix, depends of course on the anatomical relations existing between the urinary and genital organs. We may here suitably refer to two points, whose importance does not seem to be sufficiently recognised by many writers.

First, the lateral portions of the bladder, even when the organ is empty, do not correspond to the limits of the cervix, but rest on both sides upon the lower median portions of the broad ligament, loosely connected with this ligament and the paravaginal cellular tissue beneath it.[1] The neck of the womb is covered by the bladder in the lower two-thirds of its supravaginal portion (Luschka), and to a still greater extent when the latter organ is much distended.

Secondly, each ureter from its point of entrance into the bladder is for about 5 cm. toward the kidney in such intimate relation with the posterior vesical wall that every displacement of the organ moves this segment of the ureter directly with it. To use a definite anatomical expression, this association of these two structures begins just where the ureter in its forward course crosses the pelvic end of the broad ligament. This whole portion, 5 cm. long, lies between the bladder wall and the paracervical, parafornical, and paravaginal structures respectively.

From this point of view, the division of the ureter, as it is given by the *anatomists* (a pars abdominalis 14 cm. long from the kidney to the inlet of the true pelvis, a pars pelvica 12 cm. long, passing across the true pelvis to enter the vesical musculature, and a pars vesicalis, the portion within the bladder wall), deserves a certain modification for the *surgeon* in reference to its second and third divisions. For him the pars pelvica ceases at the point where the ureter, coming from the base of the broad ligament, approaches the

[1] A. Mackenrodt, 'Zeitschrift f. Geburtshülfe und Gynäk.,' Bd. 29, p. 157.

bladder, to become intimately joined with this organ. The true vesical portion begins here. Accordingly, the female ureter, 26 cm. long, may for surgical purposes be divided into an abdominal portion 14 cm., a pelvic portion 7 cm., and a vesical portion 5 cm. in length.

From the foregoing, it follows that when the bladder, together with the vaginal wall, is to be lifted up in its entirety, one must not be content with merely severing the loose connection with the cervix, but the dissection must be extended laterally to the broad ligaments and the paravaginal connective tissue. In freeing the bladder, the only fixed point is the vesical neck, *i.e.*, the place of transition from bladder into true urethra, while in all other portions the connections of these organs are unusually weak. Only in the region of the trigone is the bladder somewhat more firmly united with the vagina.

It follows, further, that when the bladder is completely raised up, the vesical portion of the ureter, according to our designation, must also take part in this dislocation. The freeing of the bladder, which is characterized by some writers as a special stage in vaginal hysterectomy, is therefore not only a separation of the bladder from the uterus, but is in a wider sense the disconnection of the bladder, together with the vesical portion of the ureters, from the uterus, and from the main portion of the broad ligaments as well as from the cardinal ligaments and the paravaginal tissues.

On account of the importance of the anatomical relations between the urinary and genital organs in their bearing on the vaginal radical operation, we deemed it advisable to investigate the matter by dissections and experiments on the cadaver. The following is a résumé of the conclusions derived from our experiments.

In looking at the course of the ureters, one notices first the pars abdominalis, having the form of an italic *f*, lying in the loose retro-peritoneal cellular tissue upon the psoas muscles, converging from the outer towards the inner edge as they descend.[1]

[1] Compare Luschka, 'Topogr. d. Harnleiter des Weibes,' 'Arch. f. Gynäkol.,' Bd. 3, p. 373 *et seq.*

Then comes the pelvic portion as above defined; this portion of the ureter, lying close up against the lateral wall of the true pelvis on each side, describes a shallow curve with the convexity outwards and backwards, the left to the inside, the right to the outside of the hypogastric artery. The curve reaches to the base of the broad ligament (lig. cardinale), and then turning more to the front and towards the middle line, passes through the loose connective tissue at the pelvic end of this ligament. Immediately after this, on a level with the base of the broad ligament, it is crossed by the round ligament, which courses away from it; close by, and in the same horizontal plane, it passes over the larger uterine vessels (uterine artery and plexus of veins), and at once enters the posterior wall of the bladder, which, as above stated, extends laterally on to the parafornical and paracervical tissues. The ureter is here intimately connected with the vesical wall, as the pars vesicalis of our description.

Thus the ureter, descending from the level of the infundibulo-pelvic ligament obliquely inwards, does not traverse the whole central connective-tissue portion of the broad ligament in a straight line, as one might conclude by looking at dissection of these structures when spread out flat.

How is this to be reconciled with the observation made by Luschka that the distance between the converging abdominal segments of the ureters becomes greater again in the true pelvis; that at a certain point, namely at the level of the fourth sacral vertebra, the separation amounts to $2\frac{1}{2}$ cm. more than at the renal end, the ratio being $11\frac{1}{2}$ to 9 cm.?

It is, however, more to the purpose to emphasize the fact that the ureter passes through the connective tissue only at the outer end of the base of the broad ligament, and, apart from this, has nothing to do with the connective tissue in the whole height and extent of its central portions.

Since the pars pelvica, immediately after piercing the ligament, becomes the pars vesicalis, it follows that every displacement of the bladder with the vesical portion of the ureters must affect the pelvic portions as far as their course

lies within the loose connective tissue of the base of the broad ligaments.

Accordingly, in raising the bladder properly, the fixed point of the ureters lies beyond the point where they pass through the base of the broad ligament, *i.e.*, on the wall of the true pelvis, on the side of the ligament nearer the kidney. The distance of this fixed point from the uterus, when

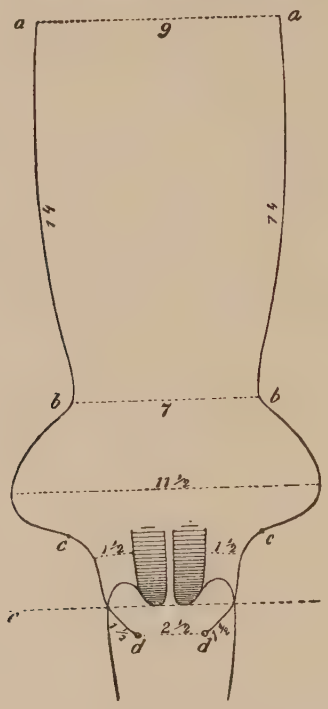

FIG. 19.—DIAGRAM OF THE COURSE OF THE URETERS (LUDWIG PICK).

a b Abdominal portion = 14 cm.; *b c* pelvic portion = 7 cm.; *c d* vesical portion = 5 cm.: *c* indicates the point of entrance of the ureter into the most lateral portion of the broad ligament.

measured transversely, is therefore the same as the whole breadth of the broad ligament, or about 5 cm. on each side.

In view of this, one may say that the bladder and ureters, after their entry into the true pelvis, and the genitalia with the broad ligaments and vessels, represent two independent and displaceable systems, separated from each other by a

connective-tissue layer, which is easily separated throughout its whole extent. *The two systems are arranged in the transverse plane, panel-like, one behind the other. The complete elevation of the bladder, especially of its lateral portions, includes also the complete freeing of the ureters up to the wall of the true pelvis, thereby giving a field of operation on each side of the uterus, corresponding to the whole width of the broad ligaments.*

When in an operation the two systems have once been separated from each other by means of downward traction upon the genitalia and their ligaments, and by pushing the bladder and ureters upwards, it is only necessary to maintain this artificial position by means of retractors or similar instruments, to insure against injury of the urinary apparatus during the further stages of the operation (separation and resection of the internal genital organs).

Experience teaches that even in the most thorough denudation of bladder and ureters, we need have no fear of disturbance of their innervation or blood supply. That this freeing of the bladder is, however, not always a harmless act is shown by certain cases in which hæmaturia occurs or retention persists for days after the operation, attributable, in part at least, to direct injury of the muscles or nerves of the organ.

But, on the other hand, the fact that nowhere has gangrene or any severe lasting functional disturbance of the urinary apparatus been observed after this severe vaginal operation, is explained by the circumstance that the anterior relations of the bladder are not interfered with, and the rest of its circumference is provided with a relatively thick layer of connective tissue which contains its nerves, and the vessels springing from the vasa hypogastrica.

That the anterior surface of this organ may also be partly freed from its connections without any nutritive or functional injury to it, is shown by the results of uterine extirpation when begun with the longitudinal incision in the anterior vaginal wall.

After the ureter crosses the pericervical plexus of veins, and passing over the art. uterina, joins the posterior bladder wall, its further course, the pars vesicalis, takes the form of a

shallow double curve along the supravaginal portion of the cervix, and approaches the vaginal vault (Fig. 19). Steadily nearing this structure, it crosses over the anterior vaginal wall at a sharp angle on a level with the deepest portion of the portio at each side. This point is about at the junction of the upper part of the vagina and the vaginal vault. Here the ureters course along the front vaginal wall at each side, wedged in between it and the bladder for a distance of 1½ cm., to reach their orifices at the angle of the trigone 2½ cm. apart. If these orifices were projected on to the vaginal wall, they would fall at the junction of the middle and upper thirds of the vaginal canal. The distance of the vesical portions from the cervix on each side, at the place where they approach nearest to it, is about 1½ cm.

When the mobile uterus is drawn down into the vagina by traction on the portio, the bladder and ureters suffer a certain displacement as well as the uterus itself. The posterior and lower bladder-wall forms—as is easily shown by introducing a catheter—a cystocele, whose size varies with the case; the converging ureters are brought nearer to the cervix because the lower segment of the uterus increasing in thickness from below upwards is drawn in between them like a wedge. *The dislocation of the bladder and ureters by traction on the womb is relatively much smaller than that of the uterine neck.* The cervix is really wedged in between the ureters, which from the downward traction are more or less on a stretch up to the pelvic wall. When the vaginal vault and the portio are drawn into the entrance of the vagina, or even beyond the vulva, far below the level of the vesical orifices of the ureters, those portions of these ducts in relation to the vagina up to their junction with the bladder assume a horizontal or even ascending direction.

In any case, when the normal mobile uterus is pulled downward, the bladder and vesical portions of the ureters must be brought closer to each other in the anterior vaginal vault. Hence upon these considerations is based the rule to *keep the primary incision close to the external os in front and—for safety's sake—at the sides also,* while posteriorly it may extend far into the vaginal vault. If the incision is carried

too far from the os externum, the ends of the anterior curve may strike the ureters while the middle may reach the bladder.

When the womb is fixed and cannot be pulled down, the bladder and ureters naturally remain in place. Here the danger of injury to the bladder lies in the primary incision in the anterior vaginal vault. The ureters, lying along the lateral fornices of the vagina, are also in danger, especially since they may be drawn still closer to the cervix by reason of paracervical indurations and cicatrices.[1]

[1] Recent statistics refer to the right ureter being more frequently injured in vaginal hysterectomy than the left. The material is so slight that it is not impossible that this preponderance is merely accidental; still, a number of explanations have been offered. Tuffier ascribes the cause to the inconvenience of applying the clamps to the right side, the instruments being pushed too far over, and so injuring the ureter.

Fournel, from several observations, bases his explanation upon mechanical grounds. First, the operator's left hand pulling on the volsellæ always deviates unconsciously from the middle line, leaving the side of the bladder and the corresponding ureter to retract from the enucleating finger. Secondly, the left hand, in a position midway between pronation and supination, inclines of itself to supination, turning the right side of the uterus and the right ureter still further away from the finger which is loosening bladder and ureter from the uterus.

Fournel's opinion that the relations of the ureters to the cervix on each side are the same, is hardly correct.

The distance of the ureters, not only from the cervix but from the uterus itself, varies, and while the difference is so slight that it has but little importance for the rules governing the isolation of the urinary organs, still, from the anatomical standpoint it is worthy of notice. Luschka says, 'Since there is a slight but pronounced deviation of the long axis of the uterus from the imaginary median plane of the pelvis, which is normal and dependent upon the position of the rectum, it must follow that one of the ureters will be closer to the uterus than the other. On account of the rectum being to the left, the deviation of the uterus is most frequently to the right, bringing it nearer to the corresponding ureter. In the exceptional course of the rectum downward, from right to left, the relations are usually reversed.' According to this the right ureter is the more liable to injury when the bladder and ureters have not been sufficiently isolated, especially in prophylactic clamping.

Further, Luschka emphasizes the fact 'that the distance of the ureters from the uterus must vary with the physiological condition of that organ,' and it is evident that cicatricial peri- and para-metritic processes, as well

Fourth Stage: Opening the Peritoneal Cavity.

If it is merely an exploratory incision, the anterior or posterior cul-de-sac, and the anterior or posterior reflection of the peritoneum, must be opened after making the vaginal incision, according to the position of the organs or structures to be palpated, whether situated in front of or behind the uterus.

The first cut with the scissors in the posterior vaginal vault often opens up the pouch of Douglas at the same time, or the finger pushing aside the peri-rectal cellular tissue bores at once through the thin peritoneal membrane. When this, which is often only too elastic, recedes before the finger, a small fold must be caught up with forceps or pincette and pulled down so that it can be opened transversely with the point of the scissors. The small wound is then widened by the finger as much as may be necessary.

If the exploratory incision is to be made in front, whether it be transverse or sagittal, the bladder and ureters must first be raised completely out of the field of operation. The anterior fold of peritoneum (plica vesico-uterina) appears at once as a thin shiny bluish-white membrane when normal, or in case of perimetritis as a thicker white tissue which, as in the posterior cul-de-sac, extends on to the uterus for a variable distance. The peritoneum, as it comes into view in the middle line, is best opened transversely, the scissors cutting directly against it; the closed scissors are then pushed into the small hole so made, and this torn widely open by spreading the handles (Fig. 20). The upper part of the fold follows the bladder, and of its own accord retracts out of the field of operation. The finger is now introduced through the opening, along the front wall of the uterus into the abdominal cavity.

---

as pathological changes in the form of the uterus from tumours, etc., must alter its relations to the ureters.

Still, after allowing the fullest recognition to these individual relations, the fundamental principle for freeing the bladder remains unchanged; viz., the most complete elevation of the organ in the middle as well as at the sides.

No matter where the exploratory incision is made, whether in front or behind, there is no important hæmorrhage encountered either in freeing the pericervical tissues or in boring through the peritoneum.

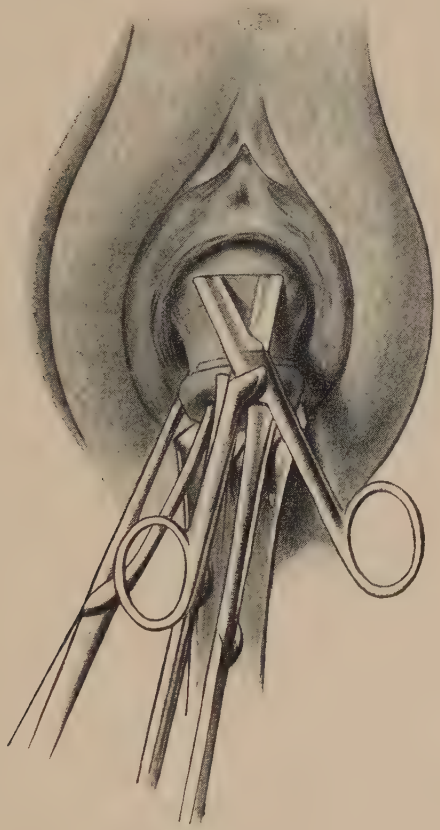

FIG. 20.—INTRODUCTION AND SPREADING OF THE SCISSORS IN OPENING THE UTERO-VESICAL POUCH.

The opening of the peritoneum is made in exactly the same way in a hysterectomy previously intended, as in one which is decided upon after exploratory incision, except that when the finger cannot bore through the posterior cul-de-sac at once, the incision in front through the plica vesico-uterina must alone suffice for the time being.

The pouch of Douglas is then opened only after the next stage of the operation has been completed, *i.e.*, the separation of the internal genital organs.

Fifth Stage: Luxation of the Uterus and Adnexa into the Vagina.

Directly after opening the anterior plica, a retractor is introduced which guards the bladder and ureters and carries the anterior peritoneal fold well up over the fundus of the uterus, so that we have no more trouble with it during the rest of the operation. One or two volsellæ are fixed perpendicularly into the middle line of the body of the uterus, close to the fundus, and the womb is now anteflexed as much as possible by one or two fingers introduced through the posterior cul-de-sac or, when this is still unopened, pressed high up against the uterus posteriorly.

By this combination of pressure from behind and traction on the forceps in front, the uterus is easily drawn out of the pelvic cavity; the organ slips through the wound in the anterior vaginal wall like a foot out of a shoe.

The dislocated uterus now lies quite free in the vagina, often, indeed, in the vulva, with its posterior surface braced against the symphysis, held above and at the sides by the broad ligaments as by elastic bands (Fig. 21). Prolapse of intestine or omentum is hindered by the retractor, and by a quickly arranged slight degree of pelvic elevation.

Sometimes, when the space is limited, it is necessary to remove the retractor in front, and the finger from the posterior cul-de-sac. In such cases the traction on the front wall of the uterus may be supplemented with good effect by pushing the portio backwards and upward by means of the forceps which are still attached to it. After the womb has been so brought forward, the front retractor is to be introduced again above and behind the uterus, since it forms the chief protection to the bladder and intestines during the whole course of the operation.

The use of the volsellæ in drawing the uterus forward is

much to be preferred to the silk sutures or sharp hooks generally employed for this purpose. When the uterine

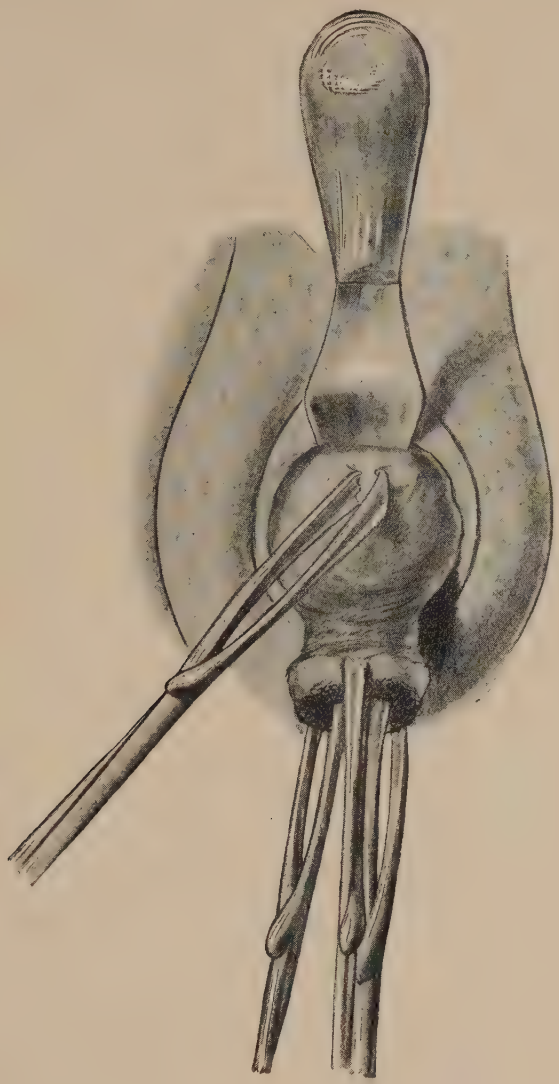

FIG. 21.—EVULSION OF THE FUNDUS FROM THE PELVIC CAVITY.

parenchyma is soft and brittle, it is sometimes advisable to lift the organ out by means of a hook fixed into it, and a

short retractor passed over the fundus on to the posterior surface.

If the posterior cul-de-sac has not been opened, the peritoneal fold is now to be severed from above, preferably by pushing a light clamp forceps through it—a method which is absolutely without danger to the adjacent organs. The points of the clamp are meanwhile guarded by a finger introduced behind the fundus from above, and by one passed into the posterior vaginal incision (Fig. 22).

Now that the womb has been completely dislocated forwards, the tubes and ovaries, sometimes healthy, sometimes diseased, are visible on its posterior surface at each side.

If the anteflexion of the uterus be increased by slight traction, one can frequently see the adnexa as far as the infundibulo-pelvic ligament, and they can thus be freed and brought out into the vagina. They may be secured by passing the finger along the isthmus of the tubes, or equally well with the ovarian forceps (Fig. 9), whose pressure is spread over a large surface, and whose elastic blades do not crush the tissues (Fig. 23).

When the appendages are fixed the adhesions must be separated first of all. For this the introduction of one (index) or two (middle and index) fingers suffices to shell out and liberate the ovaries and tubes.

For the extraction of tumours of the adnexa it is often advisable to pass one or two fingers of each hand into the abdomen. These grasp the tumour as the forceps do the child's head in obstetrics, and deliver it with the least possible injury to its structure. The liberated portions of the appendages as they come into the field are seized, secured and drawn down with ovarian forceps, without using too much force.

Bimanual manipulations, such as are employed in the usual gynæcological examination, one hand inside and one on the abdomen, are superfluous in the simple cases now under discussion.

When the uterus is mobile it is easy to pull it through the slit in the posterior vaginal vault by retroflexing it strongly,

but as a rule we prefer to dispense with this procedure. If it is to be employed, the womb must first be most carefully freed from its connection with the bladder and ureters, since

FIG. 22.—OPENING THE POUCH OF DOUGLAS BY THRUSTING A FORCEPS THROUGH FROM ABOVE.

otherwise a backward dislocation of the organ might cause a laceration of the bladder.

The procedure may be employed, for instance, where it is necessary to extirpate a uterus whose portio is absent, in which case, to protect the adjacent organs as much as

possible, one has to begin the operation by attacking the posterior uterine wall with volsellæ and scissors; also in

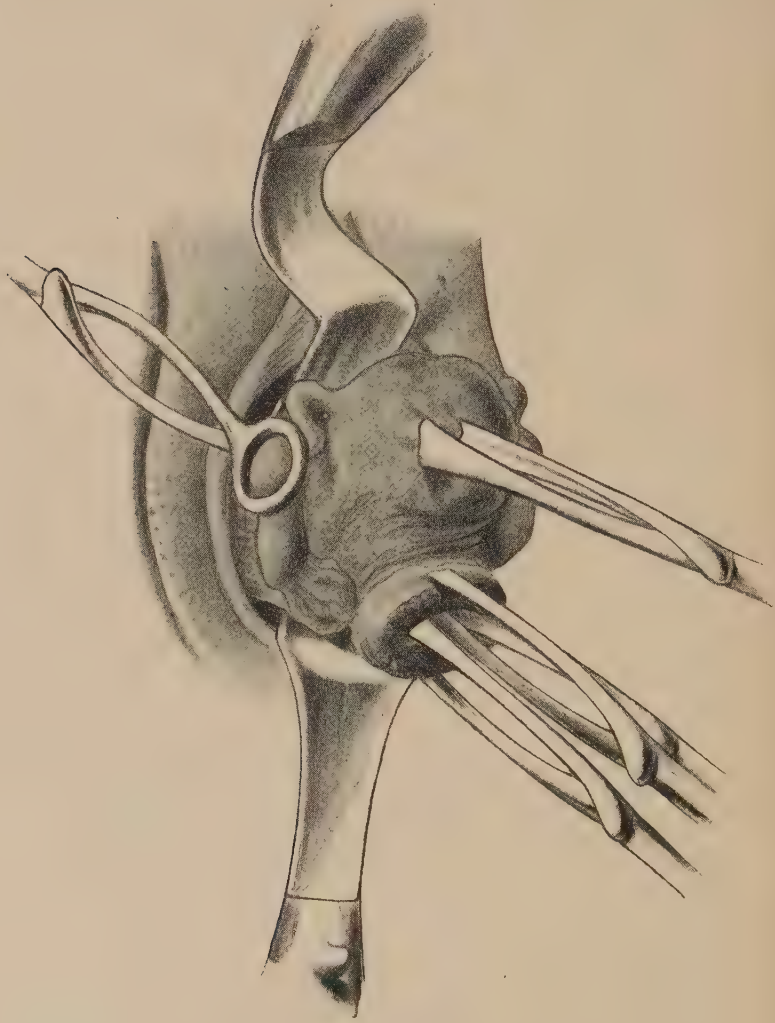

FIG. 23. — UTERUS, WITH THE APPENDAGES OF BOTH SIDES, DRAWN DOWN INTO THE VAGINA; THE RIGHT APPENDAGES SEIZED WITH AN OVARIAN FORCEPS.

cases where an extreme degree of retroflexion with fixation is present; and, finally, in posterior hemi-section of the uterus, which will be described later.

Even after the uterus and its appendages have been luxated into the vagina, the fate of the internal genitalia, so brought out of the abdomen for direct examination by sight and touch, is but little prejudiced. After possible adhesions about the tubes and ovaries have been severed, and cysts in the ovary or in the peritonitic adhesions punctured and evacuated, the operation can be suspended at this point exactly as in a vaginal cœliotomy, regardless of the more extensive denudation of the cervix just performed. The womb and appendages may be replaced, just as a dislocated limb is reduced, for up to this time none of the larger vessels have been cut off. One or both appendages may be operated upon or extirpated when inflammatory processes, tubal pregnancy, or small tumours are present. Myomata can be shelled out of the uterine parenchyma, or other plastic operations may be done on the adnexa, such as resection of the ovary, salpingectomy, etc. Finally the whole complex of indications for the vaginal cœliotomy may be fulfilled.

Up to the present time the simple anterior or posterior incision has sufficed for this method, but the uterus tolerates very well the combined procedure, *i.e.*, opening of both culs-de-sac, and perhaps in the near or remote future such a method will be 'discovered' again with its 'very important advantages.'

Following up the vaginal radical operation, we will take up the routine steps, and proceed now to the hæmostasis and excision of the organs.

Sixth Stage: Hæmostasis and Excision—The Number of Clamps and Method of their Application.

The uterus and adnexa have now been completely freed and brought down into the vagina. A pedicle has been formed right and left; but up to this point nothing of importance has been done for the control of hæmorrhage. Either the ligature or the clamps may now be employed, for when the organs have been so exposed, it is as easy to control the hæmorrhage with ligatures as with forci-pressure.

Here, as in every hysterectomy performed with the aid of the clamps, different modifications are to be considered; thus the forceps may be applied from above or from below; we may use a few only (one or two on each side) with long blades, or a greater number with short blades. As far as a general rule can be given here, the particular method to be employed must depend on the pathological condition of the uterus and appendages; but we may observe that when it is possible to first free all the parts and form suitable pedicles, not only is each of the methods of applying the clamps possible, but all are also opportune. Where this is not the case, and some of the pedicles must be secured in advance, it necessarily follows that many clamps must be used, and that they must be applied from below.

In the first case, in 'consecutive' clamping—*i.e.*, forci-pressure applied after the parts are completely freed—the *direction* of the clamps may be discussed with about the same profit as that which accrues, for instance, from the discussion of the advantages of the ligature. One is therefore not justified in laying down such hard and fast rules as does Baudron, when, as the representative of the French surgeons, he says: 'Forci-pressure is either preventive or consecutive; in the first the clamps are applied from below, in the second from above.' It is really of but slight importance in which direction the 'consecutive' clamps are introduced.

Those who operate standing will naturally apply them from above, and it must be admitted that in this way a second hæmostatic principle, torsion of the vessels, is added to that of force-pressure; for by the depression of the handles of the forceps the clamped vessels necessarily revolve in an arc of nearly 180°.

Operators who work sitting, involuntarily introduce the forceps from below, whereby the stumps are more easily and firmly pulled down into the vagina, and their extra-peritoneal position better secured. Here the traction on the pedicles forms the wound surface into a funnel, whose point lies, and must remain, extra-peritoneal and intra-vaginal.

Just as equally good results are obtained by applying the

forceps from below or from above, so also in general their number is a matter of indifference. Working on an organ which lies entirely free, it is certainly easy in practice to put on a single large clamp, reaching from the infundibulo-pelvic ligament to the base of the broad ligament, or *vice versâ*. One equally long but of lighter form may with advantage be put on behind (external to) this, to ensure against retraction of the tissue out of its grasp (Doyen). In applying these



FIG. 24.—APPLICATION OF CLAMPS FROM BELOW.

instruments under full control of sight and touch, it is difficult to see why the intestine or ureter should be in special danger, as is sometimes stated.

As a matter of fact, we advocate the application of several clamps on each side, put on from below, each one higher than the preceding one (Figs. 24, 25). In the first place, an equal degree of compression is thus made on all parts of the pedicle, giving absolute security against hæmorrhage, while the long elastic clamp, in spite of the best workmanship and

finish, often shows more or less weakness, especially near the lock. In the second place, when several clamps are used the danger of hæmorrhage after their removal is much less; and when they have been applied from below it is impossible for the elasticity still remaining in the stumps to cause a rapid untwisting of the same, and a loosening of the thrombi after the clamps are taken off.

Furthermore, in case of a retraction of the pedicle during operation, which may occur with the clamps as well as with



FIG. 25.—APPLICATION OF CLAMPS FROM BELOW.[1]

the ligature when several have been employed, it is easy to seek out and expose the bleeding-point, using the clamps already in place as retractors, and for making traction.

But, after all, we admit that such discussions are more or less of a theoretical nature, and we, like others, have had equally favourable results, whether we have used a few long

[1] The schematic Figs. 24, 25, 26, 27, 36, 37, are from drawings made by Dr. Vogel.

forceps or several short ones, and whether they have been applied from above or from below.

There is still one point in the clamp technique which experience has taught us, and which we would emphasize, namely, that in using more than one clamp for the whole

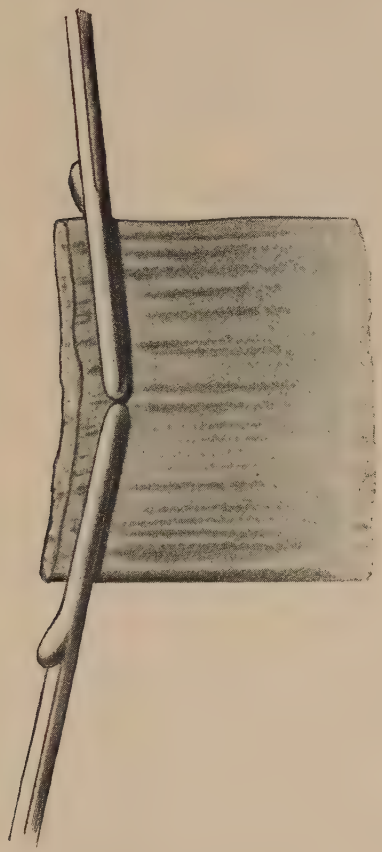

FIG. 26.—APPLICATION OF CLAMPS FROM ABOVE AND FROM BELOW—FAULTY METHOD.

width of the ligament, their direction must never be changed—that is, all must be put on from below, or all from above. Suppose that one has been applied from above, the other from below (Fig. 26): through the traction of the upper one as it swings downward by its own weight, a

laceration of the highly vascular broad ligament may occur at the point where the forceps come in contact, leading to profuse hæmorrhage (Fig. 27).

Such an event is possible when one uses, for instance, Segond's method, in which, without exception, the blood-supply to the cervix is secured previously, *i.e.*, from below, and then, after the separation of the body of the uterus, consecutive hæmostasis is applied from above. The same with the method of Quénu, who applies a clamp to the



FIG. 27.—EFFECT OF APPLICATION OF CLAMPS FROM ABOVE AND FROM BELOW.

uterine artery on each side, and then, after freeing both halves of the uterus, clamps the rest of the ligament from above.

To return to the description of the details of the operation. By means of the fixation forceps the womb is drawn sharply forward, and to the side opposite the one to which the clamps are to be first applied, unfolding very completely in this way the ligament and its vessels. It is especially important to expose the region of the uterine arteries by drawing the portio well to the opposite side.

We begin generally with the left adnexa.[1] Here, as should always be done in applying the clamps, a finger is passed along the posterior surface of the broad ligament, which is not under visual control, forming a safe guide for the posterior blade of the forceps. The finger behind prevents (as the eye does in front) any tearing or dissecting up of the ligament by the points of the clamp, and likewise guards against the dangerous inclusion of gut or omentum.

The operator passes the left index-finger through the pouch of Douglas, behind the corresponding ligament, and the first clamp is pushed up beside it into place (Fig. 28).

If, through attempts at coughing or vomiting, intestinal loops or portions of omentum are forced into the gap in the peritoneum, they are easily held back in this, as in the later stages, by the retractors, by mounted sponges, or by a moderate raising of the pelvis.

If the operator chooses to employ the long clamps, taking in the whole depth of the broad ligament, and securing all its vessels at once, after the large Doyen's clamp (Fig. 10 *a*) is in place, a lighter protective clamp must be applied to the outer side of it. Then with a few snips of the scissors the tissues are cut through to the inner side of the first clamp. A knife answers as well, or, if desired, the Paquelin's cautery.

Naturally, the direction of the clamps, when applied from below, is upward and outward.

If one intends to use several clamps, the first is applied from below to the tissues containing the uterine vessels, and then this part is cut away almost to the point of the instrument, whereby a place is made for the application of the next one above, and to the inner side of the first. In this fashion the whole ligament is included within two or three, or at the most four clamps, which are placed regularly, one at the side, and above the other, all having a parallel direction (Figs. 24, 25). From below upward each clamp lies to the inner side of the preceding one, and the general direction of all is upwards and outwards, corresponding to the surface extent of the ligament in the funnel of the true pelvis.

[1] Figs. 28 and 29 represent the right adnexa being clamped first; as a rule we begin with the left.—L. and Th. L.

To avoid retraction of the tissue out of the blades of the forceps (without reference to the better or poorer quality of

FIG. 28.—APPLICATION OF THE FIRST CLAMP ON THE RIGHT ADNEXA; THE LEFT FOREFINGER BEHIND THE RIGHT BROAD LIGAMENT.

the instruments), we make it a rule not to sever the ligament too close to the edge of the clamps, and especially not to shave it off smooth.

The absence of bleeding from the uterine end of the severed broad ligament is explained by the peculiar arrangement of the vessels: there are no important anastomoses between the upper and lower vascular areas on the same side, just as there are none between the two lateral uterine halves.

Since, as we have shown in a previous chapter, after the bladder and ureters have been completely displaced upwards, the whole extent of the broad ligament may be clamped off without danger, it is unnecessary to keep to the direction given by Baudron: 'The incisions should be made as close as possible to the uterine tissue.' On the contrary, especially in the extirpation of a cancerous uterus, one cannot remove too much of the adjacent tissue, even when macroscopically unaffected.

In dealing with the other side, the right, there are two methods. One may proceed in a manner exactly similar to that in which the first ligament was divided. The uterus, more especially the portio, is drawn sharply forward and toward the patient's left thigh by means of the fixation forceps, and the operator's left index-finger, or two fingers if desired, passed behind the right broad ligament as a guide (Fig. 29). Then, as with the other side, the successive clamping and incising follow in succession, until the last and uppermost forceps grasps the infundibulo-pelvic ligament.

Or, according to a second method, the severed left tube and ovary, together with the uterus, are rotated outwards, *i.e.*, toward the corresponding (right) thigh of the patient, about an imaginary vertical axis passing through the as yet undisturbed right broad ligament. That which was originally the posterior surface of the broad ligament now lies to the front, and is quite exposed to sight. The operator passes one or more fingers behind it as a guide, the clamps are put on, one large or several shorter forceps, as may be desired, and the ligament is cut away as described for the other side.

In this way the uterus, with the tubes and ovaries, can often be removed in less time than that required for the description; regardless of the indication, whether for cancer

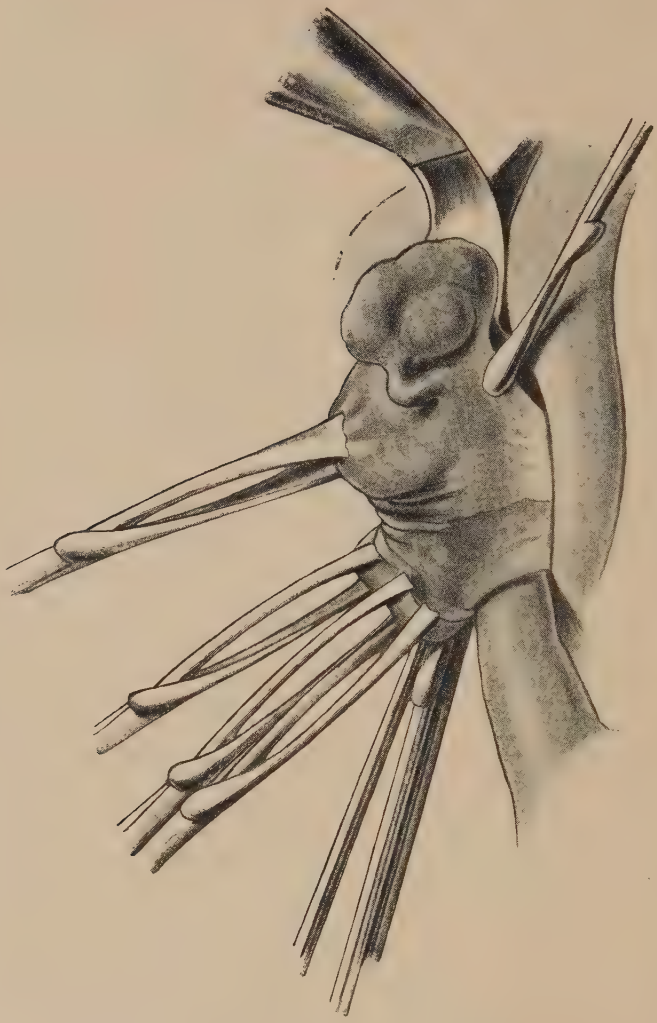

FIG. 29.—CLAMPING OF THE OTHER (HERE THE LEFT) SIDE, ACCORDING TO THE FIRST METHOD. THE RIGHT ADNEXA CUT AWAY FROM THE LIGAMENT, WHICH IS SECURED BY THREE CLAMPS. A FORCEPS ON THE LEFT INFUNDIBULO-PELVIC LIGAMENT AS A 'MARKER.'

of the body or neck of the uterus, multiple myomata, inflamed or suppurating adnexa, or actual tumours of the latter.

The fundamental condition necessary for this relatively

easy and simple operation is merely the free mobility of the uterus. Therefore, when this is only interfered with by the large size of the cystic diseased adnexa, or by intra- or extra-peritoneal cysts with serous, bloody, or purulent contents, it is easy to procure the conditions for this form of the radical operation: before the extirpation the cyst contents may be evacuated with a trocar, or, better still, through an incision which, if possible, should be so placed as to be in the line of the incision about the portio which is to follow; or, after the vaginal incision is made, the cyst may be simply bored into with the finger. In some cases the cystic tumour can be exposed before being opened; although here the first stages of the hysterectomy upon a more or less immobile organ must often be performed under rather inconvenient and disturbing conditions, as, for instance, when it is necessary to work high up in the vaginal vault in a greatly-narrowed space, etc.

The evacuation of the serous, hæmorrhagic, colloid, dermoid, or purulent contents of cysts of the appendages materially facilitates the vaginal radical operation, especially for the removal of the diseased appendages themselves, in those cases also where the tumour, without itself in any way affecting the mobility of the uterus, is, owing to its size, firmly wedged in the pelvis, and is but slightly, if at all, movable. Here its diminution can be effected under visual control, at any stage of the operation, though most conveniently after the complete separation of the uterus.

As the contents of the sac flow out at the lowest point, the opening in the vagina, no fear of peritoneal infection need be entertained, for the vagina forms a natural outlet along which the fluids escape safely without coming in contact with the peritoneum.

Even after the most extensive evacuation of this sort we use no irrigation or antiseptic whatever, because, according to our experience, the mere sponging away with sterilized gauze does away with the danger of infection. In a previous chapter it has been shown how rapidly and safely the whole wound surface heals extra-peritoneally with the open-wound treatment.

Finally, we must bear in mind the results of recent investigations concerning the inoculability (by implantation) of the epithelial elements of the so-called colloid cystoma of the ovary;[1] in evacuating such tumours in the course of the vaginal operation it is better to avoid an incision, employing merely puncture, in order to lessen the risk of inoculation of the wound surface.

There is another curious phenomenon to be referred to at this point. Sometimes after resecting the uterus and appendages there is heard a peculiar hissing sound—stridor vaginalis.

It occurs as the result of air entering the abdominal cavity through the vagina, due to the change of respiratory pressure, when, as in some cases, there is a valve-like closure of the vaginal vault by flaps of peritoneum.

Seventh Stage: Revision of the Wound—Introduction of the Gauze—Procedure in Case of a too Large or too Small Opening in the Vaginal Vault.

After removing the uterus and adnexa, the only point requiring attention is the absolute control of hæmorrhage. The wound in the anterior vaginal vault and in the anterior paracervical tissue bleeds but slightly, excepting in special hyperæmias of the genital area, pregnancy, puerperium, hyperplasia of the uterus, operation during the menstrual period, etc. This may be regarded as quite an exceptional occurrence. Here, as in the bleeding from the posterior vaginal wound, and the thick layer of perirectal connective tissue, a few light hæmostatic forceps suffice to control the oozing. During the application of these instruments, the posterior vaginal wall, which is often rolled inwards, can easily be everted with the light forceps, one part after the other.

Up to the moment in which the internal genital organs are resected, this hæmorrhage has no importance, for up to this time the vessels concerned have been compressed by the uterus.

[1] J. Pfannenstiel, 'Carcinombildung nach Ovariotomien,' 'Zeitschrift f. Geburt. und Gynäk,' 1894, Bd. 28.

For isolating the edges of the vaginal wound, as well as for exposing the clamped pedicles, the clamps themselves, together with the retractors, render good service. They are carefully assorted and separated into three groups, one corresponding to the posterior, the other two to the lateral walls of the vagina. On the anterior vaginal wall, as above stated, clamps are very seldom applied. The cavity thus formed (Fig. 30), which may be enlarged inwardly by pressing the points of the forceps outwards and away from each other, forms at every point a transverse section of a pyramid, which is open at the top. The long retractor is now introduced along the anterior vaginal wall (Fig. 30). The whole wound surface, with the intestine and omentum in the background, now lies quite exposed to view, and ready for the application of any instrument or instruments that may be desired.

Formerly we often united the margin of the posterior wound in the vagina to that of the overlying peritoneal edge, as is generally done in the usual ligature method. At present, however, we do not ascribe any value to this particular form of 'embroidery,' and, after opening the pouch of Douglas, do not trouble ourselves any further about the peritoneum.

Now comes the revision of the pedicles. In order to guard against a later hæmorrhage, the traction of the clamps on the pedicles, whether from their own weight, or effected by the assistant, is now relaxed. To obtain complete relaxation of the pedicles, it is, in fact, advisable to push the forceps slightly inwards. In this way any small vessel which may have escaped the clamp, but is still indirectly compressed by torsion or traction, will show itself now, instead of later, when the patient is in bed. The patient, if in the Trendelenberg position, is lowered, and kept here quietly for a few moments. This pelvic elevation itself may in some cases, especially with a weakened heart, be enough to check hæmorrhage from the smaller vessels.

Should one of the pedicles continue to bleed, it must be provided with a new clamp, or several if necessary. If by accident a clamp has slipped off, or a branch of the uterine

or ovarian artery, or a vein in the broad ligament, still bleeds, one must not waste time with a temporary gauze tampon, whose only effect is to obstruct the view of the field; far

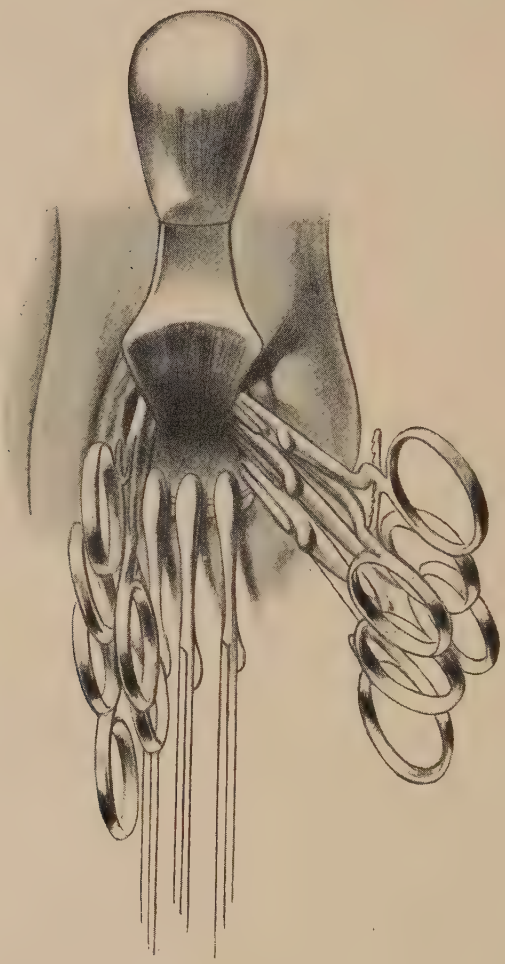

FIG. 30. — EXPOSURE AND SPREADING-OUT OF THE WOUND BY THE CLAMPS AND RETRACTOR.

less should one trust entirely to such a measure. The forceps already in place are carefully separated from each other, and the bleeding-point exposed. Then the oozing

blood is quickly sponged away, and a fresh clamp applied under direct visual control.

This unimportant kind of hæmorrhage at the end of the operation is not oftener met with in the clamp method than in the ligature method, and a death from hæmorrhage during or after a vaginal hysterectomy with the clamps is the fault of the operator, not of the method.

If one of the ovarian arteries is torn off during the delivery of the adnexa—an accident which possibly occurs often with those operators whose qualification for the vaginal radical operation consists mainly in their possessing the clamps—the hæmorrhage from the retracted end of the vessel can be checked only by a ventral laparotomy.

After all the bleeding has ceased, the clamps are again used as retractors in the manner above described, and any fluid or blood that may have collected is wiped out with mounted sponges. Then with an ordinary long dressing forceps, or clamp, a strip of sterilized gauze is introduced into the space between the clamps (Fig. 31). The central strip is knotted at its outer end so as to distinguish it from the others. It is passed well upwards, pressing back the intestinal coils and the omentum, and separating the wound surface and the points of the clamps from the abdominal cavity. The strip is quite loose, and to avoid retention of the discharge, or peritoneal irritation (reflex vomiting), must not be packed in too firmly, since it is primarily a drain and not a tampon. Then the front vaginal wall, which is generally somewhat inverted, is smoothed out with a retractor, and along with the anterior flap of peritoneum from the vesico-uterine space is lifted up while a second strip of gauze is introduced, being carried up to the edge of the vaginal wound, between it and the clamps. This strip is of the same length as the first, but is only double instead of quadruple. A third and fourth are introduced between the clamps and each lateral wall, and finally a fifth along the posterior wall under the forceps.[1] In every case the

[1] Lately we have simplified this drainage; we introduce now, as a rule, only the central strip, dispensing with the other four. The results are identically the same.—L. and Th. L.

strips should be counted, so that afterwards none be left behind, when with a wide vagina or an unusually large opening in the vault one or two more than usual have been used.

Even if such an oversight is not directly dangerous, a forgotten piece of gauze may delay the process of healing, and, as a foreign body, increase the secretion in an undesirable manner, until finally a vaginal irrigation reveals the source of the trouble.

Before each strip is introduced, the corresponding vaginal region is exposed by lifting the clamps and pressing in a retractor, and then freed from clots by sponging with a gauze pledget. Finally, all portions of the vaginal wall are smoothed out in this way, and lifted up by the strips, which form a protecting mantle of gauze for the soft parts.

The anterior vaginal wall, after being raised into place, forms more particularly a protecting membrane for the denuded base of the bladder, while the gauze lying along the posterior wall forms a bed for the clamps (which by their weight tend to fall back towards the perineum), and prevents the corresponding tipping upwards of their points.

We have found this form of dressing, or, better expressed, packing and care of the wound, satisfactory in every respect. With such drainage there is nowhere a dead space, or reservoir for stagnating secretions; all the fluids must flow outward along the natural oblique pelvic outlet. Further, any hæmorrhage that may occur is recognised at once by the escape of blood externally, since the previous separation of the vaginal walls prevents the occurrence of a hæmatocele, and makes it impossible for a fatal internal hæmorrhage to remain concealed.

The number of clamps left in place in such practically simple cases as we are now describing varies from four to ten.

The procedure as described for this stage of the operation is liable to some modification when the extirpation of the uterus and appendages is begun with a longitudinal (anterior colpotomy) instead of the oval incision. Here, after checking the hæmorrhage from the stumps, the paracervical

tissue, and the edges of the vaginal wound, the central gauze strip is introduced, and then the flaps of the incised anterior vaginal wall are to be united with a continuous catgut suture, or else brought into apposition by the use of an extra clamp or two. In case of marked hypertrophy of the vaginal tissues, a suitable flap is to be excised from each side of the longitudinal incision, or, when necessary, such a resection can be made in a similar way, even when the longitudinal

Fig. 31.—Introduction of the Central Strip of Gauze.

incision was not previously made. The posterior wall may be treated in the same way if it is thought advisable.

Sometimes, after the oval incision, the opening in the upper part of the vagina is either too small or too large. When too small, it is best remedied by a median incision carried through the upper part of the vaginal wall. When too large, as not uncommonly happens when portions of the vaginal flaps have had to be resected for carcinoma, it is

advisable to reduce the opening by a few sutures, or by the use of clamps.

We state most emphatically, however, that in no case do we make a complete union of the anterior and posterior walls, as is done by some operators who do not recognise the guiding principle of our method.

For this reason we discard Rouffart's modification.[1] This writer proposed recently to close the peritoneum from the vagina after the hysterectomy was finished, by bringing the median portion of the two walls together by means of one or two clamps.

Care of the Patient directly after the Operation —Arrangement of the Bed, etc.

A special chapter has been reserved for the description of the after-treatment, but it may be useful to refer to a few points here in regard to the treatment of the patient immediately after the operation.

While yet upon the operation table, the catheter is passed, not merely to evacuate what urine may have collected during the operation, but principally to ascertain if the bladder is injured in any way. A more or less bloody tinge to the urine is found sometimes in severe cases where the displacement of bladder and ureters was made difficult by inflammatory or cicatricial processes in the surrounding connective tissue. It indicates a certain amount of contusion of this organ, and disappears of itself on the following day. Bloody discoloration of the urine is therefore absolutely no evidence of a laceration of the bladder wall; likewise the absence of urine in the bladder, after the operation, does not prove anything.

In case perforation or laceration of the wall of this organ is suspected, an immediate vesical irrigation decides the question promptly and surely. When an operator meets with such an accident—in case of a mobile uterus it can only result from gross carelessness; with fixed, especially carcinomatous, uteri it may, however, be difficult to avoid—the

[1] Ed. Rouffart, 'Journ. Médic. de Bruxelles,' No. 1, 1896.

bladder wound should be sutured at once, through the vagina, or by means of supra-pubic section, according to the situation of the injury.

Occasionally with a rigid vagina and a too vigorous pressure on the perineal retractor, small perineal tears may be produced, which are best united at once with one or two stitches.

Special care should be taken in carrying the patient from the operation table to the bed. While this is being done, an assistant should support the clamps with his hand. In bed the patient is laid flat, with the legs slightly abducted.

The bunch of clamps is wrapped in a sterilized napkin to protect the thighs from contact with the metal, and the whole mass supported on a small cushion of cotton-wool or sterilized gauze. By the adoption of this little precaution, we have never had a pressure necrosis of the vulva or vagina, such as described by Lafourcade.

A square pad of wood-wool, anointed with vaseline, is placed under the nates to protect the skin from wetting and excoriation by the oozing wound secretion.

For many patients it is useful, as well as a great relief, to support the knees from the first by a pillow, so that the thighs are abducted and flexed without any muscular effort, avoiding in this way the rigidity of the abdominal muscles. The head, trunk, and pelvis are on a level with each other; the latter is not elevated, because we wish to be sure of the free escape of the wound secretions.

We discard catheterization, and introduce a permanent soft catheter after the operation only under special conditions which render the first procedure difficult for the nurse and painful to the patient. Such are cases in which the urethral orifice naturally lies close to the front vaginal wall, or where it is strongly pulled down by the clamps, or, finally, where there is such a mass of instruments that the orifice is hidden from view and is inaccessible. For this purpose the Pezzer soft-rubber catheter has answered very well.

The catheter drains into a flat vessel at the side of the clamp handles, and is removed at the same time as these

instruments, usually within twenty-four or forty-eight hours. During this two days' retention we have never observed the formation of incrustations of urinary salts or any other obstruction within its calibre, and we therefore see no disadvantage in its employment in this way.

CHAPTER IV.

REMOVAL OF THE ADNEXA AND ADHERENT UTERUS WITHOUT MORCELLATION.

THIS method applies to the extirpation of the uterus *in situ*, when its descent is hindered by peri- or para-metric infiltration, or disease of one or both appendages. It is not, however, the method of election for all cases that come under this category, but comes into use only when the circumstances of the case forbid the adoption of a technically easier procedure—in other words, when we are prevented from using the means by which, in the vaginal radical operation, every form of fixation may be overcome, *i.e.*, morcellement.

Therefore the sole indication for this procedure is the immobile carcinomatous or sarcomatous uterus in which every mutilating operation must be avoided on account of the danger of cancerous inoculation. A cancerous womb which is *mobile* should be removed by the method previously described, which is incomparably easier; so also such an organ when merely indirectly fixed by cystic disease of the appendages (pyo- or hydro-salpinx or cyst of the ovary) should be freed by puncture, incision or perforation of the sac from the vaginal incision, and then treated as a mobile organ.

Where, on the contrary, the adherent unilateral or bilateral cystic tumours are too unfavourably situated for preliminary evacuation through the vagina, or where direct fixation of the uterus exists, either alone or in addition to these cysts, the only course is to extirpate the uterus *in situ*, regardless of its fixation.

The method is equally applicable in dealing with carcinoma or sarcoma of the uterine neck and of the uterine body.

Since morcellement must be wholly avoided in malignant new growths, it follows that the vaginal extirpation in these cases is only possible in dealing with organs of a certain size, *i.e.*, such organs must be capable of passing through the vagina without any artificial reduction of their bulk.

When a radical operation still seems possible with a uterus too greatly enlarged by tumour formation to pass the vaginal outlet, one's choice is limited to abdominal hysterectomy. Whether the enlargement depends on the corpus carcinoma itself, or upon complicating myomata, the cancer is guarded by healthy myometrium and perimetrium forming a sort of capsule, so that there is no danger of its dissemination during removal, even in an abdominal extirpation.

If, however, the space necessary for the vaginal delivery of this sort of tumour unmutilated can be gained by a vagino-perineal section, we should prefer this to ventral laparotomy on account of its advantages, previously discussed. In passing, we may state that such are the only occasions in connection with the vaginal radical operation when we are not able to dispense with perineal section.

The same indications hold good either for the abdominal or the vaginal extirpation in dealing with cancer of the uterine neck, complicated by fibromata of the body, likewise in cancer of the cervix or body affecting a normal or slightly enlarged uterus, when at the same time a narrow or stenosed vagina exists. For in cervical cancer, even when small and quite localized, neither the body of the uterus nor even the fundus must be mutilated, for, as the most recent researches show, the cancer cells may have been carried in the lymph or blood-stream as far as the fundus. Compared with abdominal laparotomy, the vagino-perineal incision is here the lesser of the two evils, hence the former remains as the method of necessity for large carcinomatous uteri only.

Another question is whether abdominal extirpation is specially indicated when the carcinoma has attacked the parametrium, the uterus not having undergone any material enlargement.

Besides our practical experience, the following theoretical considerations speak strongly in favour of the vaginal

route: Firstly, there can be no doubt that the ligamentous tissue can be as widely extirpated by the aid of the clamps as it can be from the ventral incision, namely, right up to the lateral wall of the pelvis; secondly, there is a greater possibility of inoculation during the abdominal operation, especially on account of the danger of the dissemination of cancer cells by the needles and ligatures which are passed through the ligaments. Finally, the general advantages of the vaginal over the abdominal route are decidedly in favour of the former.

The chief difference between the operation described in the preceding chapter, the extirpation of the mobile uterus, and this method of removing the adherent organ without morcellation, lies in the necessity of primary clamping in the latter operation. Here the preliminary isolation of the organ is out of the question. The clamps now take the place of the ligature purely upon practical grounds, since they have the great advantage that by their use even the gravest fixation of the womb is not an insurmountable obstacle to extirpation. Naturally, one has to work at both sides of the uterus, with many short clamps, corresponding to the ligatures.

In a certain number of cases the immobility quickly diminishes after the first stages of the extirpation, either because the fixation is wholly or chiefly limited to the lower uterine segment, or because after opening the peritoneum the finger can be introduced and adhesions and cicatrices broken up; or, finally, because adherent cysts high up in the pelvis can then be broken up or incised, their contents evacuated, and the uterus thus liberated. The walls of such cysts, when opened, are to be seized and controlled with forceps, just as is done with the Nélaton forceps in an ordinary ovariotomy.

When under such circumstances a certain mobility of the uterus is obtained in the course of the operation, one should always try again to first effect the separation and pedicle-formation, and to secure the vessels secondarily.

The details of the procedure are as follows: All brittle, disorganized carcinoma masses are to be first cleared away

from the field of operation, avoiding meanwhile all rough manipulation which might injure the healthy structures. In cancer of the body of the uterus, the cervix is to be closed by fixing the lips of the portio together with a strong volsella. When the vagino-perineal section is to be made, the fresh wound should be covered with sterilized gauze, and this held in place by a retractor during the whole operation. The precept to keep all the instruments—retractors, fixation forceps and clamps—as much as possible in the same place, avoiding unnecessary movements, applies to all hysterectomies for malignant tumours, not merely under the above circumstances, but also without the perineal section.

After the fixation forceps have been securely applied, for which one must depend mainly on the posterior lip of the portio, or the posterior uterine wall, an incision is to be made round the cervix, the form and course of which will depend entirely on the seat and diffusion of the cancer. Then follows the denuding of the cervix, which is infinitely more tedious and difficult than in the cases first described. Often enough the uterine neck is walled in on all sides by firm and tense inflammatory products which fix the uterus in front as pericystitis, laterally as parametritis, on the fundus and posterior surface as perimetritis, periproctitis, or by cicatricial masses which obliterate the entire pouch of Douglas. Through the formation of intra- or extra-peritoneal indurations there is often nothing of the pouch of Douglas remaining; it is destroyed. Blunt dissection with finger or raspatory does not suffice in such cases; the short firm bands of scar tissue must be divided throughout with the scissors.

These inflammatory changes are the cause of the very considerable difficulties often encountered in liberating the bladder and ureters, and they make it impossible to get through the posterior cul-de-sac with the first incision.

Here, as in all grave inflammatory processes in the pelvic connective tissue, particular caution is required to prevent lacerating the bladder or intestine. Cicatricial bands about the rectum and the lower portion of the sigmoid flexure may cause bulgings of their walls into the perirectal tissue, which

from their analogy to similar processes occurring in the œsophagus must be regarded as traction diverticula, and which may be very easily penetrated through hasty attempts at isolation of the genital organs.

The pelvic as well as the vesical portions of the ureters may become adherent to the uterus in consequence of inflammatory processes due to the tumour, or independent of it. The ureters may be fixed in hard cicatrices, or they may be displaced by the subsequent retraction of this scar tissue. In the same way their normal course and position may be disturbed by the malignant tumour itself when its outgrowths project into or towards the broad ligament, or by fibroids which complicate the uterine sarcoma or carcinoma.

From this it follows that the directions given for liberating the ureters lying in normal tissue must frequently be more or less departed from, when conditions similar to the above are encountered in the pelvis.

It is certain that the occasional injuries of the ureters in operations for carcinoma uteri are to be referred to such displacement of these organs, and not merely to the cancerous erosion. In the very effort to radically free the patient from her malignant trouble, the necessary consideration of these changes of position is only too easily overlooked.

When the vesico-uterine fold has been reached, it is to be opened with the scissors points, and a long retractor introduced; or when this is prevented by adhesions in the anterior cul-de-sac, the necessary space is to be obtained by tearing the adhesions away with the finger, reaching in this way the free abdominal cavity in front.

Then, after the bladder and ureters have been raised up, the uterus and its ligaments become more accessible. Still, this organ is not yet loosened from its bed; it cannot yet be brought forward to the symphysis; in fact, it can be but little moved out of its position. Nothing could be more dangerous and ill-timed than to now attempt to forcibly prolapse it by pressure on the abdominal parietes above, or by strong traction with the fixation forceps from below. The ligaments, which are sodden and brittle from the

inflammatory changes, even in the absence of malignant infiltration, might easily be torn through, and, by retracting, give rise to extremely dangerous hæmorrhage. Pus collections about the uterus may be only too easily ruptured, and while the organ remains in place, their contents may flow into the abdomen, instead of being safely discharged through the vagina, as is the aim of the operation, and as happens when it is properly carried out. Finally, when the fundus or adnexa are firmly adherent to the gut, violent manipulation may lead to a rupture of the intestinal wall, which naturally could not be controlled at this stage.

In certain cases it is impossible, in the first stage of the operation, to raise the bladder and ureters sufficiently to open the vesico-uterine fold without danger to the urinary organs. Here only a small portion of the cervix is at first isolated without opening the abdomen in front or behind it. One must for the time being dispense with further attempts at mobilization, and first secure the vessels entering the denuded cervix—that is, resort to primary clamping.

The operator pushes one or two fingers behind the portion of the ligament containing the uterine vessels, or, in case the pouch of Douglas has been opened, through this cul-de-sac. Under this guidance a short stout forceps is clamped on the sound tissue at each side, and the corresponding portion of the ligament cut through (Fig. 32). Sometimes, when both culs-de-sac are obliterated, this cut opens the abdominal cavity at the side and behind.

In many cases, as stated, the freeing of the cervix alone is sufficient to make the remainder of the organ mobile; in others, the finger can be pushed through the cul-de-sac in front or behind into the peritoneal cavity, and adhesions broken down which previously fixed the body, either directly, or indirectly through the diseased adnexa. Finally, in another set of cases it now becomes possible to accomplish this by evacuating, under visual control, cysts and abscesses lying high in the pelvis.

The uterus and appendages, which in the presence of cancer are always removed entire, are then freed by the method previously described, pedicles formed and dealt with

secondarily; the uterine vessels alone are primarily clamped. If the posterior cul-de-sac is still unopened, a closed forceps should be forced through from above, the finger and retractor meanwhile guarding the intestines (Fig. 22), or it may be cut through from one side with the scissors under visual control.

There remains yet to be described the method of extirpa-

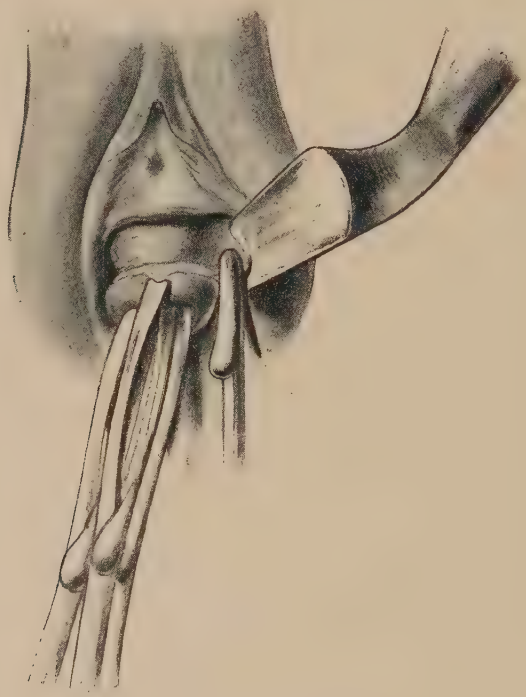

FIG. 32.—PREVENTIVE CLAMPING OF THE LEFT UTERINE VESSELS.

tion in those cases in which, even after primary clamping and isolation of the cervix, it is still impossible to set free the body of the uterus. This is the pure form of the method to which this chapter is devoted.

The procedure is exactly similar to the ligature method; that is, one clamp is applied after the other, each one higher than the preceding, and the tissue as it is clamped is cut through step by step.

When the fixation is chiefly or wholly unilateral, after clamping the uterine arteries, it is better to liberate the less affected side first, successively clamping and resecting the ligament from below upwards, until this side of the uterus, with its tube and ovary, is free. After this the uterus, still fixed on one side, can be partially drawn down into the vagina, together with the portions already freed, and there is now room to work along the posterior surface of fundus and tube. Perimetritic bands, tubal adhesions and connections with the gut, if present, can be reached and divided, so that the field of operation is now sufficiently exposed to allow of the shelling out of adnexal tumours of the more affected side. If the posterior cul-de-sac is still intact, the thickened peritoneum is to be cut through at this point from the right or left.

Occasionally in these cases primary clamping of one side of the cervix suffices. The uterine neck then becomes free enough for the uterus and appendages to be wholly liberated through the posterior cul-de-sac, and the simpler method of enucleation can now be employed without further recourse to prophylactic hæmostasis.

If, on the contrary, the fixation is of equal extent on both sides, or if it consists mainly of dense perimetritic encapsulation, the clamps must be symmetrically put on, one after the other, on both sides, and the corresponding depth of the ligament divided each time. In this way the uterus can be gradually drawn further down, the direction of its long axis remaining unchanged, until finally the lateral cornua are reached. If the adnexa can now be delivered, they are to be brought out, their pedicles secured and clamped at each side, and then resected along with the uterus.

It is, however, of no consequence in this method if the womb be first extirpated, either alone or with the adnexa of one side only, the remaining portions of the diseased appendages being afterwards removed by themselves. They are seized at the tubal isthmus with the finger, or, better, with an ovum forceps, freed from adhesions as far as possible, and another forceps applied to the side of the first. This process is repeated until the ovary and the rounded pavilion,

often intimately bound together, are brought out into the vaginal canal, and the pedicle secured.

It is very useful, in dealing with all inflammatory processes of the appendages, to apply a short clamp to the infundibulo-pelvic ligament beyond the pavilion as soon as the tube and ovary have been brought into the vagina. This marks the direction and the terminal point of the row of clamps on the corresponding side (Fig. 29), and prevents the retraction of the ovary or the end of the tube, which was previously firmly adherent to the lateral pelvic wall.

Another general rule in liberating the adnexa is to be mentioned here, namely, that this procedure on the left side must always be executed with particular caution, and all violence must be avoided. In the diffuse form of pelvic peritonitis there is often a very intimate fusion of the sigmoid flexure with the internal genital organs; the frequency of this condition has not been sufficiently recognised. Evidently the extension, by continuity, of the inflammatory process from the broad ligament to the peri- and para-sigmoidal tissues depends on their close anatomical relations, or, rather, on the direct transition of the mesentery of the flexure into the 'mesentery' of the tube and ovary. The contraction occurring in the inflammatory products must finally lead to a direct fusion of the organs. Tube and ovary are drawn into the convolutions of the flexure, and become intimately adherent to the wall of the gut.

The definite and complete hæmostasis which immediately follows the resection of the womb and appendages is here, as in all cases of pelvi-peritonitic adhesions, not so easy and simple as in the class of operations first described. Besides the marked hyperæmia of the chronic inflamed pericervical and perivaginal tissues, the adhesions themselves are, as a rule, extremely vascular. The bleeding shreds attached to gut and omentum must often be firmly compressed for some time with mounted sponges before the oozing can be checked. Thick and firm bands of adhesion, especially when connected with the omentum, after being brought into the vaginal opening, can be most conveniently secured by ligatures before being cut away with knife or scissors. For

the rest, one separates the adhesions with the finger, tearing them through, and sometimes having to use considerable force. Sometimes during this process such a profuse bleeding starts that the field of operation is hidden in a few seconds. Mounted sponges pressed down quickly one after the other soon clear away the blood and expose the bleeding-point.

Very occasionally a trifling parenchymatous hæmorrhage from the lacerated adhesions persists in spite of compression and waiting; the gauze strip lying nearest the bleeding-point should then be more firmly packed in, and one or two extra ones added. The Mikulicz tampon might also be employed here with advantage.

Under such circumstances we delay the return of the patient to bed in order to be sure while she is still on the table that the bleeding is completely checked.

CHAPTER V.

REMOVAL OF THE UTERUS AND APPENDAGES WITH THE AID OF MORCELLEMENT — SPLITTING THE UTERUS— MEDIAN SECTION OF ONE WALL.

For the vaginal extirpation of the internal genital organs, the large group of morcellating procedures come into operation when the womb is directly or indirectly fixed, but free from malignant new growths. In every case the chief object is to first bring the organs down into the vagina, their separation thus preceding the control of hæmorrhage. All the mutilative procedures are intended solely for this purpose, and hence are not methods for indiscriminate use. One dissects or divides up the uterus only until it is possible to deliver the remainder in one mass.

It is difficult to understand why the technique should be burdened with an auxiliary operation in cases where the organs can be extirpated entire according to the method first described. In the same way, it must be considered a fundamental principle always to use the simplest form of morcellement that will suffice for the individual case.

The simplest of the mutilating operations consists in the splitting of one uterine wall, preferably the anterior (hemisectio uteri mediana). The mechanical effect of this procedure has already been explained in detail in the section devoted to the general technique (see p. 47). After this longitudinal section, the uterus can be unrolled and flattened out in a way similar to that in which the organ is spread open according to Virchow's post-mortem technique. In this way a uterus which is too large for flexion and delivery through the vagina is in the first place flattened and rendered able to pass, and secondly the organ is set free, and room is afforded for the finger to be introduced over the fundus into the abdominal cavity to reach perimetritic adhesions or the adherent adnexa.

Whilst the most extensive of the mutilating operations—morcellement in the original sense of the word—is for some cases indispensable, *i.e.*, the method of necessity, other procedures always come into competition with section of the uterus, and sometimes with morcellement itself, as methods of election; such are operations of the type of the old Czerny procedure in hysterectomy; but they are themselves mutilating operations. We refer to hysterectomy with the aid of vagino-perineal section, perineal incision, sacral and para-sacral incision, sacral resection, or finally ventral laparotomy. When these different methods are employed, the diseased organs are indeed removed intact, but the healthy structures remaining behind are injured, with the frequent result either of danger during the operation (hæmorrhage) or of later functional disturbances (paralysis).

For this reason the adoption of such measures seems inconsistent, and we therefore choose the harmless but not less effective method of dividing up the uterus itself. Malignant tumours of the uterus are alone excluded from this category; ventral laparotomy or perineal incision must be here employed.

The indications for the operation under discussion, the simplest of the incising methods, are: hyperplastic or fibromatous uteri up to the size of a man's fist, uteri fixed by parametritic or adnexal disease, or a combination of hyper-

trophy and fixation. A condition which is absolutely necessary for the successful employment of this procedure is that the uterine tissue be not too soft or friable, as, for instance, in the puerperal state, for then the volsellæ simply tear through the parenchyma, and do not fix or hold it at all.

In opening the uterus, the anterior wall is the one chiefly concerned. Doyen proposes this as a general method for all hysterectomies. It was he who developed the method in its details as a universal procedure, and described it later at the Brussels Gynæcological Congress. Section of the posterior wall alone is but rarely employed; sometimes it may be useful for a retroflexed, hyperplastic uterus when the anterior wall is strongly pressed up against the symphysis.

One proceeds as follows: The portio is seized by two volsellæ, one at each commissure, and in case the womb is firmly fixed a third may also be applied on the middle of the posterior lip (Fig. 33). These forceps are allowed to remain as landmarks during the whole operation.

An oval incision is made round the portio, stripping off the perivesical and perirectal tissues from the cervix. The pouch of Douglas is opened, if possible, and cysts or abscesses, if present, are evacuated at the same time.

Since the later manipulation concerns only the front wall of the uterus, the forceps on the portio are drawn strongly downwards and backwards, and the perineal retractor is removed. If there be any difficulty in stripping away the paracervical tissue in front, one must neither forcibly raise the bladder and ureters, nor make too violent traction on the portio. It is better to liberate at first only one or two centimetres of the cervix from its connective-tissue bed, and then introduce one point of the scissors into the cervical canal, and split the cervix in the anterior median line just to where it has been freed. A retractor held by an assistant obliquely against the uterus marks the border-line and protects the bladder at the same time. It is not necessary to use a grooved director as a guide for the scissors. A fresh volsella is at once placed on each lip of the longitudinal wound, rotated outwards, and then held by the assistant at

each side with moderate traction. Then the precervical tissue is still further dissected off, and the bladder and ureters correspondingly raised out of the field of operation. In dissecting upwards it is easy to push the closed scissors flat along the uterus like a wedge, whenever a free point is found; then the points are spread so that the puncture wound is broadened and deepened. The retractor is then pushed into this gap, prising up the investing lamina of

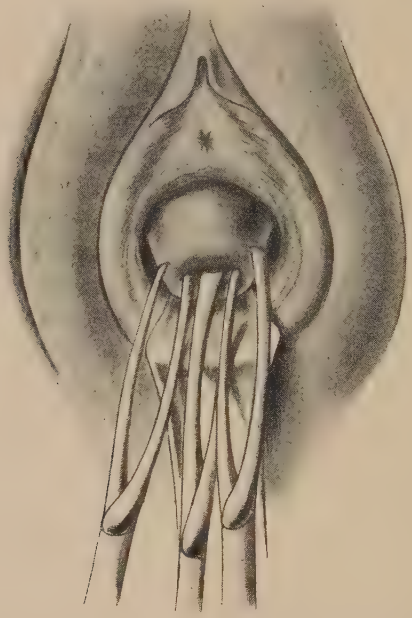

Fig. 33.—Method of Fixing the Portio Vaginalis with three Volsellæ.

tissue along with the bladder above it. In this way a further segment of the uterine neck is liberated from its connective tissue, and now this part is to be split up the middle, continuously with the first incision, up to the point marked by the retractor. New forceps are applied to the lips of the wound as high as possible, or the lower ones are removed and replaced higher up.

This lateral application of the volsellæ has the advantage that, in spite of the large resultant of their combined traction,

the tissue grasped is not too strongly pulled on, for the traction is divided among the several instruments; the tissue does not tear out as might happen if one applied the same force to one single instrument placed in the middle line.

Advancing in this manner, the whole anterior wall of the uterus is gradually split up, when necessary clear to the

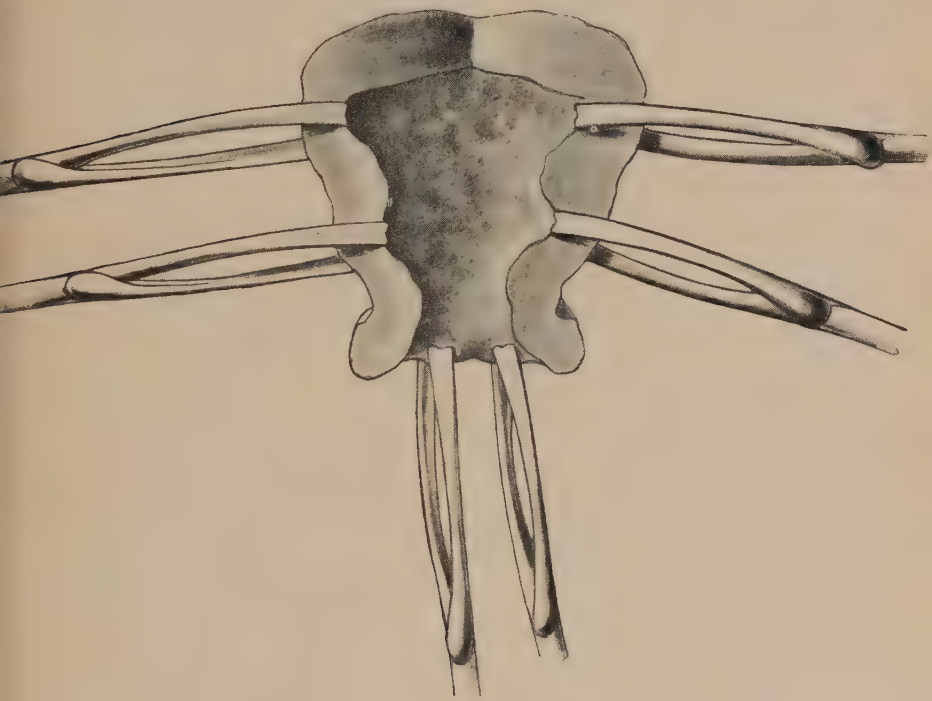

FIG. 34.—THE UNROLLING OF THE UTERUS RESULTING FROM SECTION OF ITS ANTERIOR WALL.

fundus (Fig. 34), and the peritoneum is opened with the scissors as soon as it becomes visible. One volsella is applied above the other each time the sagittal incision is lengthened, so that these forceps are always climbing higher, the bladder and ureters being meanwhile securely protected by the retractor. Hæmorrhage is prevented by the downward and outward traction upon the forceps.

Often it is not necessary to carry the longitudinal incision

of the front wall as high as the fundus, for a uterus, even when twice as large as normal, if not directly or indirectly fixed, can be brought into the vagina as soon as room is made for it by splitting and unrolling its lower segment, employing meanwhile traction from below and leverage forward, with the fingers or retractor passed behind the fundus.

A uterus fixed merely by its size becomes mobile by being so unrolled, and can then be delivered *conduplicato corpore* into the vagina, the cervix being at the same time pushed upward and backward by means of the forceps attached to the portio. In certain cases as, for instance, uncomplicated uterine hypertrophy or pyosalpinx developed in the ampulla of the tube, the median section is easily carried up as high as the fundus in a few moments, with two or three cuts of the scissors, and the organ can then be immediately displaced forward. At other times, on the contrary, after a tedious denudation and slow and careful opening of the anterior wall, the organ cannot be tilted forward even by forcible traction.

When the uterus is hypertrophied beyond a certain point, the unrolling does not even yet make its delivery through the vagina possible. It can then be sufficiently reduced in size by the enucleation of fibroids through the sagittal incision, by excising V-shaped masses from the uterine wall (Doyen), or by removing longitudinal strips from the wall, including its whole length and thickness. But more of this later; these are methods that lead to morcellement itself.

After the fundus comes into the vagina, the finger or ovum forceps is to be passed into the abdomen, through the gap above the uterus, and the appendages seized and brought out under visual control. If the fixation can be overcome during the section of the uterus by working through one or other cul-de-sac, the delivery of the tubes and ovaries is made decidedly easier. Otherwise the front wall is at first split completely, and then one finger is introduced above the fundus, and, aided by the fingers of the other hand in the posterior cul-de-sac, separates the adhesions on the posterior surface of the uterus and about the adnexa. Cysts and abscesses are shelled out of their connections, and the

appendages, together with the fundus, brought into view by means of the ovum forceps.

If the complete liberation of the internal genital organs, that is, the separation of the adhesions about the uterus and the enucleation of the sclerosed or hypertrophied adnexa cannot be effected in this manner, the splitting of the womb must be still further continued. One proceeds now to the next method, the total median section of the uterus.

Where, however, after the above procedures, the uterus and appendages have been delivered entire,[1] the posterior cul-de-sac is to be perforated with a clamp in case it was not opened during the earlier stages of the operation. But by no means can it be perforated without danger immediately after the vaginal incision, as is recommended by some writers (Baudron and others).

It seems unnecessary to make a separate description of the section of the posterior wall, a procedure which is occasionally of service in the rather infrequent cases mentioned earlier in this chapter. The method is just the same as that here described; the womb is retroverted, care being observed previously to free all its vesical and ureteral connections, so as to avoid laceration of these organs.

When all the structures have been brought into sight and suitable pedicles for the same secured, one can proceed to hæmostatic measures. Doyen, the father of this method, begins at the left, and applies from above two long elastic clamps at each side, each grasping the whole breadth of the broad ligament. We, as usual, employ several forceps, beginning from below.

[1] When the tubes are solidly adherent, they are sometimes torn off at the isthmus during these manipulations. Still, they remain connected with the uterus by portions of the broad ligament, so that the delivery of the internal genital organs is practically complete.

CHAPTER VI.

COMPLETE MEDIAN SECTION OF THE UTERUS.

In describing the previous method, it was stated that under some circumstances the opening resulting from section of the anterior uterine wall, and the increased mobility due to its unrolling, do not suffice to bring the bands of adhesion about the uterus and the enlarged or atrophied adnexa within reach. And when the direct or indirect fixation cannot be overcome by working from the posterior vaginal incision through the firm cicatricial tissue, then the section of the anterior wall must be continued through the fundus and along the posterior wall, dividing the uterus into two symmetrical halves, and so making a broader passage for fingers and instruments.

If the fixation of the uterus be chiefly indirect, due to advanced changes in the adnexa with retraction, the divided halves of the uterus will be drawn strongly toward the sides of the pelvis by the adherent and shortened appendages. The gap will then be all the wider, and there will be all the more room for the enucleation.

Moreover this halving of the organ, splitting both walls to the fundus, is always to be used when the section of the front wall alone seems dangerous or inconvenient in presence of strong direct or indirect fixation, or in case of a narrow vagina. In order to symmetrically incise both walls from *below*, one must of course be able to get through the posterior cul-de-sac without endangering the rectum. When this has been done, and both walls of the uterus incised in the middle line beyond the internal os, the divided lower uterine segment forms a Λ-shaped gap in consequence of the traction upon the sides; through this breach the finger can now free the uterine body above for the safer continuation of the splitting process.

From these considerations, the total median section of the womb is indicated in the extirpation of uteri not larger than a man's fist, when complicated by bilateral ovarian tumours

or inflammatory or suppurative diseases of the adnexa, with marked pelvi-peritonitic fixation of the uterus and appendages. It is further indicated where the immobility of the uterus is due to the large size of the appendages, which cannot be sufficiently diminished through the vaginal incision alone, nor even after the section of the anterior uterine wall; for instance, when the adnexa are the seat of thick-walled, multilocular fluid collections.

The advantages of this total section are so great that in a large number of the severest inflammatory diseases of the adnexa and pelvic peritoneum (complicated pelvic abscesses), one may succeed in enucleating the entire internal genital organs without resorting to primary hæmostasis. By this method we have been able to prove that our 'enucleation procedure' can be executed in such cases, and we have therefore practised and developed it by preference.

Regarded historically, the idea of the median section originated with Peter Müller,[1] who proposed it in carcinoma of the uterus, for the easier ligation of the broad ligaments. After this, Quénu[2] employed it in vaginal hysterectomy for pelvic suppuration. His principle was to split both walls at the same time. In his first cases he applied a primary ligature to the uterine arteries at the beginning of the operation, but at present he uses a short heavy clamp for this purpose.

Apart from the mere division of the uterus, our total median section has nothing in common with Quénu's method. Contrary to Quénu's practice, we proceed from the incision of the front wall, directly over the fundus on to the posterior, and remove not merely the uterus, but the adnexa as well, and apply the first clamp only after all the parts have been delivered.

Our method is as follows: First the anterior wall is divided with the scissors from the external os to the fundus, and the adhesions about the uterus separated as far as possible. Then the line of the first incision is continued backwards and downwards, splitting the fundus and posterior

[1] Peter Müller, 'Centralblatt für Gynäkologie,' 1882, No. 8.

[2] Quénu, 'Annal. de Gynécol.,' 1892, Tom. 37.

wall as far as this can be done without endangering the neighbouring structures, particularly the rectum. The finger or retractor introduced behind the fundus guides the incision and protects the rectum from injury. Strong volsellæ are fixed on both edges of the wound, and the divided fundus pulled strongly downwards and forwards. The field of operation is well exposed, and the scissors are guided by the sense of sight as they are pushed forwards, dividing the whole posterior wall down to the cul-de-sac, the posterior surface of the uterus having been meanwhile freed from its perimetritic adhesions. If the posterior cul-de-sac was not opened at the beginning of the operation, a closed clamp is now to be pushed through it from above, and the wound enlarged by opening the forceps as it is drawn back. The portio is next pulled forward, and a finger working up through the cul-de-sac from below, against the assistant's finger or an écarteur above, finally makes a safe way for the scissors. The posterior wall of the cervix is now split in the middle line, and the first stage of the operation is accomplished.

The uterine segments retract laterally from each other, springing out toward the pelvic wall on each side, especially if the appendages are shortened and adherent, and the operator's fingers have now a broad free space. If the posterior cul-de-sac, as is sometimes the case, has resisted all attempts to penetrate into it, it can now be split in the middle at the same time as the posterior wall of the cervix. During this manipulation the rectum is to be guarded, the uterine halves drawn forward and away from each other, and the whole field exposed to view; from the median opening, the lateral portions of the cul-de-sac are to be incised at each side.

In passing, it may be stated that in the different forms of the vaginal radical operation, the time and manner of opening the posterior cul-de-sac vary surprisingly. It may be opened by the first incision in the vaginal vault, bored through from here by the finger, perforated from above by a clamp after the enucleation of the whole or the divided uterus, incised from one side; or, finally, it may be opened from the line of the median section of the womb.

The difficulties previously existing are now disposed of if the fixation of the uterus was chiefly direct, *i.e.*, perimetritic, and the adnexa can now be easily brought out. In cases also of indirect fixation dependent on the adnexa, the latter can now be reduced in volume and enucleated, a procedure previously impossible. In liberating firmly-adherent pus-

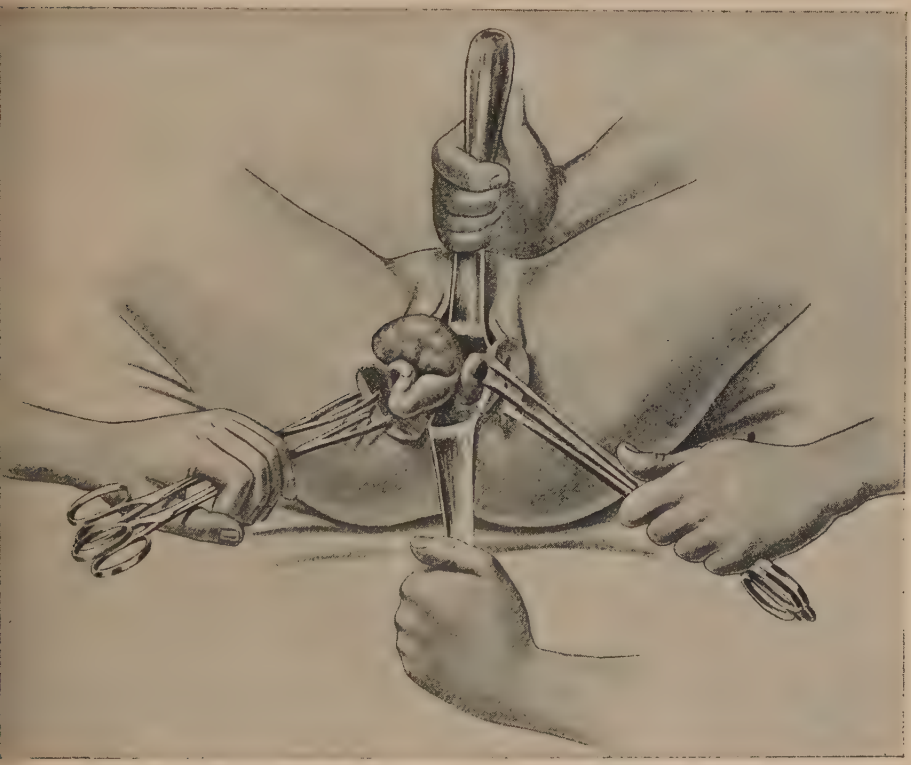

FIG. 35.—THE DELIVERY OF THE ADNEXA OF BOTH SIDES AFTER COMPLETE MEDIAN SECTION OF THE UTERUS.

tubes or ovaries, both hands are generally employed, and it is a useful practical point, for example, in enucleating the appendages of the left side, to work with the left index or index and middle fingers behind, and with the corresponding fingers of the right hand in front of the adnexa. Commencing at the isthmus of the tube, with moderate traction on the half of the uterus of the same side, the adhesions are separated, and

the cysts opened and shelled out; as the parts are liberated, they are seized and controlled by ovum forceps. The bimanual manipulation is particularly easy and effective after the median section of the uterus, which gives a broader and more adequate space. Generally the side which seems to be the less involved is to be first liberated, as in this way more room is obtained in which to work at the less favourable side.

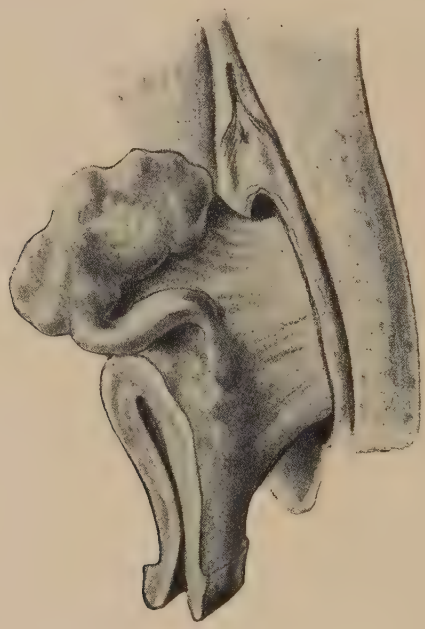

FIG. 36.—FIRST POSITION OF THE LEFT BROAD LIGAMENT: ANTERIOR SURFACE EXPOSED.

In this way the whole of the diseased internal genital organs are finally brought out at the vulva in two symmetrical halves, without the application, so far, of a single clamp.[1] Besides the compression of the edges of the wound in the uterus by the volsellæ, the vessels supplying these structures are constricted by the traction on each

[1] In exceptional cases, when the cervix is strongly fixed by adhesions, it may be an advantage during the splitting operation to clamp the uterine arteries primarily, and amputate the cervix. It is then much easier to proceed with the median section of one or both uterine walls.

half of the organs; and the torsion, combined with traction (Fig. 35) must have a similar hæmostatic effect.

The advantage of this method is now shown in the ease with which the pedicles are formed and dealt with. If desired, one may often include the whole broad ligament from its base to the infundibulo-pelvic ligament in one single clamp applied external to the suppurating tube and purulent ovary. The clamps may be so applied to each ligament that its anterior (Fig. 36) or posterior (Fig. 37) surface is brought into view. During this manœuvre the

Fig. 37.—Second Position of the Left Broad Ligament: Posterior Surface exposed.

surface of the ligament, which is not visible, is guarded by the finger placed behind it (Fig. 38).

Hæmostasis may also be neglected for the time being, even when, as occasionally happens, portions of a cyst wall or rotten pyosalpinx are torn off during the enucleation of the adnexa. Where such an accident is feared, it is always better to secure the tissue in advance by grasping it with an ovum forceps.

In this way, in spite of the soft condition of the appendages, it is possible to bring out the firmly-adherent ampulla

of a pus-tube, or a portion of a cyst wall, and so make the operation a thoroughly radical one.

However, we would particularly warn against overdoing such efforts. Naturally, one must dispense with the removal of old cicatricial products which have become united to the bony or muscular wall of the pelvis. In certain cases the sclerosed tubes and ovaries themselves may through con-

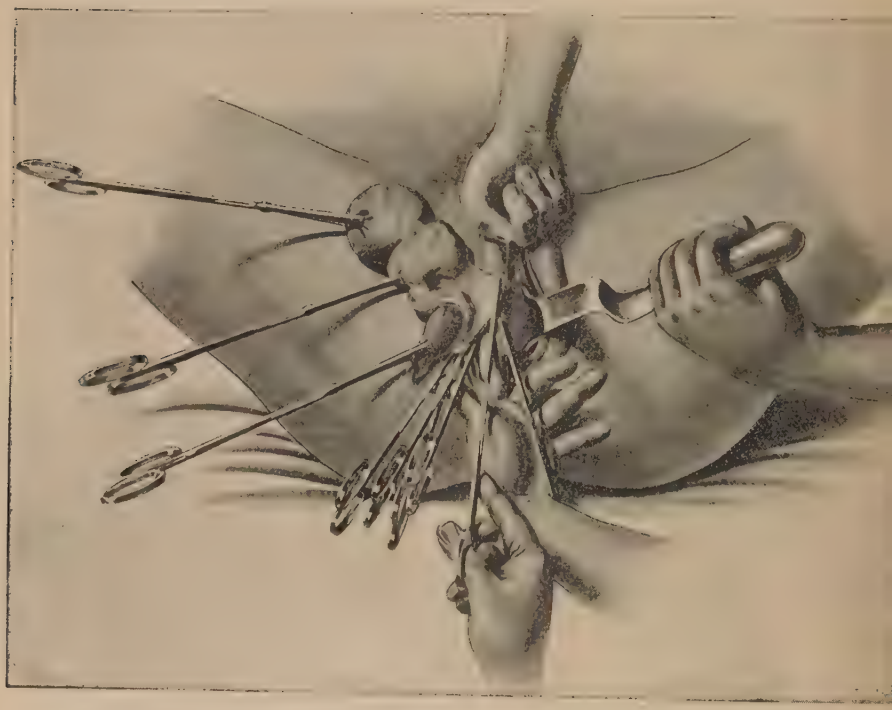

FIG. 38.—APPLICATION OF THE CLAMPS ON THE LEFT SIDE, IN THE POSITION SHOWN IN FIG. 36. THE RIGHT HALF HAS ALREADY BEEN CLAMPED AND CUT AWAY.

nective-tissue metamorphosis have become inseparably fused with the thickened pelvic connective tissue. So also, in shelling out abscesses or trying to remove tissue shreds, one must take into consideration the extent to which the bladder or intestinal wall may take part in the formation of the abscess wall, and how much of their continuity is affected. As previously explained, the sigmoid flexure is

the most liable to be involved in such processes. To attempt to radically extirpate the abscess or the remaining shreds of tissue in such cases simply means the formation of a vesical or intestinal fistula; whilst, on the other hand, owing to the extra-peritoneal mode of healing, these surfaces will cleanse themselves later and cast off the shreds of adhesions, granulation tissue and pyogenic membrane.

In a small number of cases of the kind mentioned earlier in this chapter we have, like Quénu, divided the uterus by means of corresponding incisions along the anterior and posterior uterine walls. After the explanations of this 'antero-posterior section,' it hardly needs a further detailed description. One thing is to be emphasized, and that is, that in this procedure (Quénu's) there is a special danger of injuring the rectum during the mesial section of the posterior wall of the cervix. When Douglas' pouch is obliterated by firm masses of scar tissue, the points of the scissors may perforate a traction diverticulum of the rectum, or even wound an adherent loop of small intestine. For this reason we never force this method of total section of the womb; other and safer methods of morcellation are then to be employed.

Finally, it may be mentioned that in some cases both halves of the divided uterus may be tilted backwards, just as it is sometimes done in the case of section of the posterior wall alone (p. 127); for instance, when this method of splitting is employed for a strongly-retroflexed uterus with fibroids.

Figs. 39, 40, illustrate the method and the efficiency of total median section of the uterus.

CHAPTER VII.

MORCELLATING OPERATIONS (TRUE MORCELLEMENT).

1. Symmetrical Morcellement with V-, Y- and Parallel Incision.

We divided the morcellating procedures (see p. 46) into a regular and an irregular morcellement, the latter being the operation in the exact and limited sense of the word. The method to be next described represents the simplest of the

Fig. 39.—Vaginal Radical Operation with Complete Median Section of the Uterus.

Fig. 40.—Vaginal Radical Operation with Complete Median Section of the Uterus.

regular or symmetrical operations, and forms the connecting-link between the median section of the uterus and true morcellement.

The indication for this form of symmetrical morcellation is presented when we have to deal with a regular and symmetrical enlargement of the uterus due to fibroids or general hyperplasia of the organ, the size being not greater than that of a child's head. The mere section of one or both walls in this case cannot reduce the size of the organ enough to allow of its delivery through the natural obstetrical outlet. The middle line serves as the basis of this dissecting procedure, and the lateral regions, the only ones where hæmorrhage is to be feared, are to be avoided. The V and Y incisions are also of use in the case of *asymmetrical* enlargement of the uterus up to the size mentioned above. The line of direction of the morcellement does not then coincide with the sagittal plane of the body, as in symmetrical hypertrophy, but rather with that of the uterus.

Thus, the operation is chiefly indicated for enlarged and mobile uteri, or such as may be quickly rendered mobile by the use of the method; fixation depending merely on the volume of the organ yields, of course, to this process of diminution. It can also be occasionally applied with advantage where the uterus is directly fixed.

One proceeds first with the incision round the cervix, and with its isolation, according to the rules already given; and when the bladder and urethra have been lifted up out of the way, the cervix is split along the front wall just as in the opening of the uterus. At this point it is sometimes possible to reach and enucleate a submucous or intra-mural fibroid (Doyen's conservative vaginal hystero-myomectomy).

If the enlarged womb can be drawn down, and the neighbouring organs protected by retractors, the median incision is now to be continued up to the fundus, and the effect of this opening of the organ tested in regard to the possibility of tilting the fundus forwards. If this is found to be difficult, the transverse diameter is now to be diminished by resecting, on each side of the sagittal wound, regular, longitudinal strips from the whole length and thickness of

the anterior wall. The parenchyma is seized with volsellæ, a strip is split off with the scissors, and before it is completely severed new forceps are applied to the sound tissue further on (Fig. 41). Working in this fashion, the breadth of the organ can be evenly and very materially reduced.

This symmetrical dissection involves the whole length and thickness of the anterior wall, and is particularly efficacious

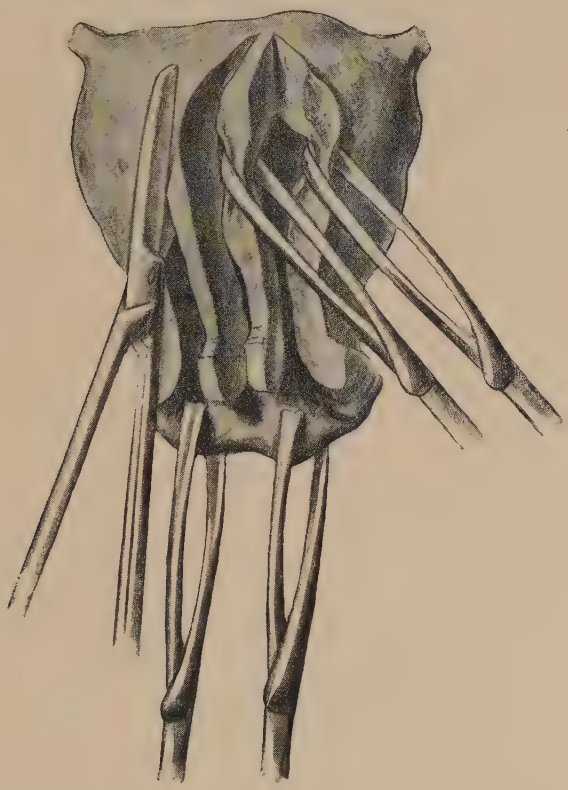

Fig. 41.—Morcellation of the Anterior Wall of the Uterus by Removal of Vertical Strips.

when the hyperplasia is of the more regular form. To this must be added a second variety of regular morcellation, which consists in the excision of wedge- or rhomb-shaped masses of the uterine wall, and which is to be adopted when the hypertrophy is localized more especially in the fundus—*i.e.*, in wedge-shaped uteri.

Sometimes after a more or less extensive splitting of the front wall, the excision of a single large or small V-shaped mass suffices to give the organ the desired mobility. The lines of incision then present the appearance of a Y. If this simple variation proves insufficient, one must fall back on the methods developed by Doyen and Segond, and described by them under various names. A glance at the illustration (Fig. 42) shows Doyen's method — 'ablation successive des fragments losangiques et cunéiformes.'

In this case the sagittal division of the uterus is dispensed with from the first, or, at any rate, is given up as ineffectual after section of the cervix.

In place of this, when it can be safely done, the operator begins at the middle of the anterior cervical lip, or at the end of the median incision if one has been made, and carries two incisions upwards and outwards, which diverge symmetrically from the middle line, resecting in this way a V-shaped mass from the front wall. The wedge is severed from its base above, and the organ is so diminished that not infrequently the fundus can be brought through the vagina without further trouble. When this is not the case, the flap is to be resected in form of a rhombus, the lips of the wound at each side grasped by volsellæ, and further masses of similar outline excised as in the accompanying Fig. 42. The forceps are placed gradually higher, fixing the edges of the wound, and the part to be resected, and drawing the uterus more and more into the vagina, exactly as in the median section of this organ previously described. The entire mass removed from the anterior wall finally represents a large wedge, with the base above.

In Segond's morcellement wedge-shaped pieces are cut away from the anterior wall, each one of which, contrary to Doyen's method, has its *apex* towards the *fundus*. Before being resected, each wedge is fixed at its base with a volsella. The final result of such a morcellation is shown in Fig 43. A Δ-shaped mass, with its base downwards, has been removed from the anterior wall.

In dealing with a uterus which is both enlarged and fixed, after the front wall has been dissected away by one of the

above methods, and more space and some mobility of the organ has been thus obtained, the finger is to be passed over the fundus, adhesions broken up, the appendages liberated, and all the parts delivered.

Segond has called his method 'central cuneiform excava-

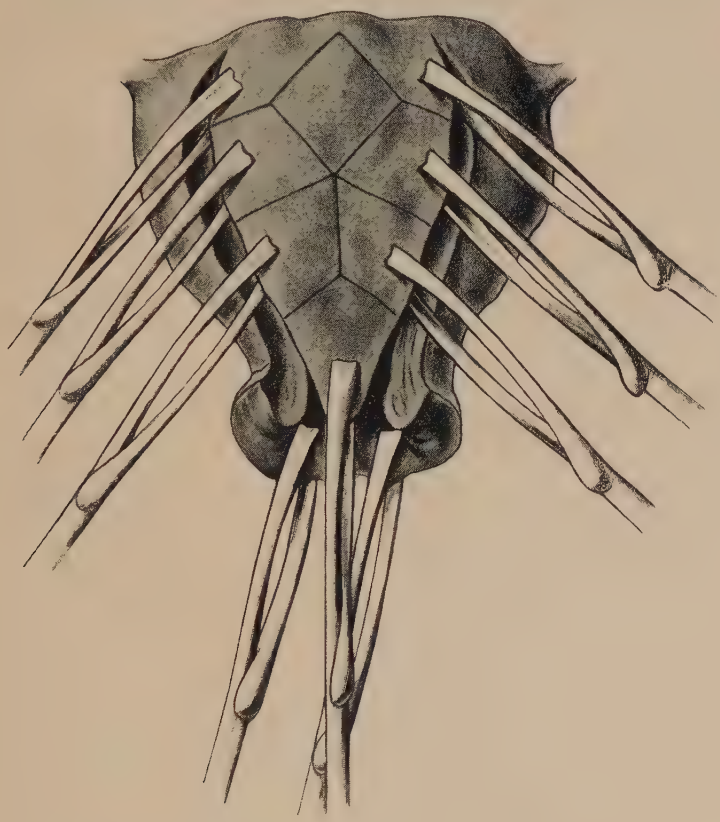

FIG. 42.—DOYEN'S METHOD OF MORCELLEMENT. (After Doyen, *l.c.* Fig. 34, p. 87.)

tion,' in spite of the fact that it really has nothing to do with an excavation, central or otherwise, nor with the resection of cone-shaped pieces. The true 'central cuneiform excavation' comes under the methods of irregular morcellement, and is chiefly useful in the piecemeal extirpation of fibroids, as we shall see farther on.

The misunderstanding arising from this rather inappropriate name caused Segond to explain his position in an article in which he said: 'The expression "central excavation" does not signify that the uterus is excavated from its centre towards the periphery, but rather from the peritoneal surface towards the cavity.'

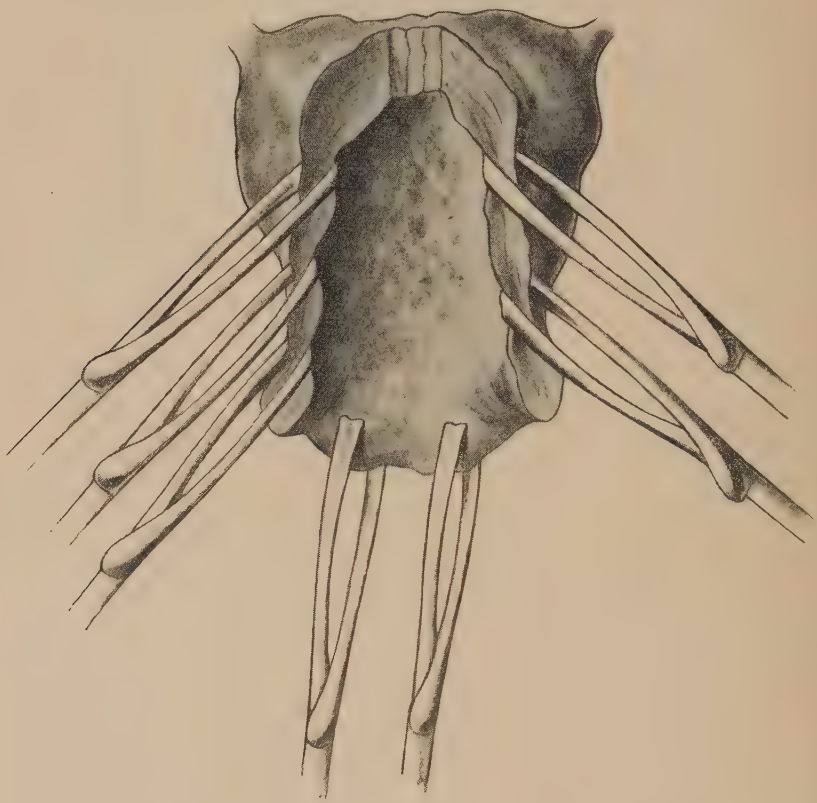

FIG. 43.—SEGOND'S METHOD OF MORCELLEMENT: FINAL STAGE.

Those who use and compare the different methods of regular morcellement, the strip-like resection of the anterior wall, or, in suitable cases, Doyen's or Segond's procedure, will be convinced that the execution of a true geometrical division of the organ, like that shown in Fig. 42, is only rarely practicable.

In his method Segond always ligates the uterine arteries

primarily, and the cervix is always extirpated before dissecting away the corpus.

We claim, on the contrary (as explained in Chapter VI., Part II.), that for us neither this nor any other form of morcellation stands in a definite relation to any given plan of hæmostasis. As far as these methods can be used to advantage, *i.e.*, as far as they are technically easy and without danger to adjacent organs, secondary hæmostasis is sufficient in the majority of the cases. As soon as the fixation of the uterus has been overcome by the aid of one or the other form of morcellation, one proceeds just the same as in removing the organ entire, or after the simple median section; the pedicles are formed, clamped off, and divided.

When the fixation is chiefly paracervical, it is necessary to secure the uterine arteries primarily, and liberate the cervix first, so that the uterus can be drawn down and the body of the womb brought within reach. Occasionally in such cases, in order to reach the upper part of the uterus at all, it is necessary to amputate the cervix as soon as its vessels have been secured. For this, one of the combined methods, to be described later, is employed.

These methods of regular morcellation, which we have mentioned as applied to the anterior uterine wall, may of course be employed for the posterior wall when this is especially involved in the hypertrophy or new growth.

During this operation it is absolutely essential that the structures adjacent to the posterior wall (rectum, and possibly adherent loops of gut), be separated with a blunt instrument, and protected by the finger or retractor. Here, as in the operation on the front wall, strips, wedge- or rhomb-shaped masses, can be removed, or fibroids enucleated from the parenchyma.

CHAPTER VIII.

BILATERAL SECTION OF THE UTERUS, AND TRANSVERSE EXCISION UNDER PRIMARY HÆMOSTASIS (PÉAN'S CLASSICAL MORCELLEMENT).

SINCE this method presupposes the primary control of the vessels, it is for us always a method of necessity, a *dernier ressort,* as it were. Nevertheless in many cases, including some of the most serious ones, it is the only operation which can be employed to the patient's advantage.

The indications for this procedure include the severest inflammatory and suppurative diseases of the uterus, appendages, and pelvic peritoneum, especially the worst forms of pelvic suppuration. It is indicated for uteri not larger than a man's fist, when the organs are bound down by cicatricial fibrous masses resulting from plastic pelvic peritonitis, so that all mobility of the organs is lost ; and also when this condition is complicated by double pyosalpinx, ovarian abscesses of both sides, or multiple intra- or extra-peritoneal abscesses with or without rectal or vesical fistulæ.

Péan's systematic morcellement, which he advocated with insufficient discrimination for every form of pelvic suppuration, as well as for carcinoma of the uterus, is at present discarded to some extent. Methods of treating pelvic suppuration have come into use which, in comparison with the castratio uterina, are simpler, although just as radical, while morcellation must be excluded in dealing with uterine cancer. Still, his method is of permanent value in the treatment of the cases first mentioned. It has led to the development of the other morcellating operations, even although the principle of primary hæmostasis, which he so firmly held to in morcellement, is now only partially adopted.

Whenever in course of the classical Péan's operation it becomes possible to enucleate the parts primarily, we employ a combined method, such as Segond's procedure, lately described by Baudron : removal of the cervix after primary

hæmostasis, and delivery of the corpus after section of the anterior wall, or after 'central conoidal excavation'; in this way primary and consecutive hæmostasis are used in combination. If, however, it is necessary to complete the operation wholly according to Péan's method, the feature which distinguishes it from all other procedures is that at no time does one have to deal with mobile or enucleable parts. Still, we maintain that for many conditions the complete carrying out of Péan's method is the only suitable and practicable procedure.

When the anterior and posterior surfaces of the uterus are intimately adherent to the adjacent structures, it is safer for these latter not to use any cutting instrument at first in the uterine parenchyma, but only in those portions of it whose vessels have first been secured under constant visual control. By this means hæmorrhage from such regions of the womb is out of the question, and it is now ready for morcellation in its whole extent, while in the piecemeal extirpation of the fixed organ the volsellæ would only partially control the hæmorrhage. They might compress the vessels, but could not close them by traction on account of the fixation.

The method is as follows: Volsellæ are placed, one on the anterior and one on the posterior lip, or one is applied in front and two symmetrically behind; in any case, the lateral commissures of the portio should be left free. This is followed by oval incision and isolation of the cervix. As it is often difficult to break through the firm and strong paracervical fibrous layers, scissors or knife must be freely used in liberating the cervix; and here especially is the rule to be observed always to work directly against, or even in, the uterine tissue. It must be remembered that here there is no little danger of injuring the neighbouring organs; bladder and rectum are fused to the cervix by cicatricial processes, and the ureters are not only surrounded by indurated masses, but are displaced by the retraction of the tissues, and often drawn close against the uterine neck. Hence one must not try to forcibly dislocate the bladder and ureters upwards at once to the full extent in the endeavour to reach the anterior

peritoneal fold, nor should the finger be forcibly thrust through indurated masses in the posterior cul-de-sac, even if the opening of cysts and abscess cavities by this manipulation be ever so desirable. Very often, indeed, large multilocular collections of fluid are evacuated in the first attempts to get through into the pouch of Douglas.

What we have now to aim at more particularly is to free the vaginal mucous membrane at each side of the cervix in front and behind the ligaments, far enough to obtain an equal space on each side corresponding to the portion of the cervix already liberated. This lower, first isolated part of the broad ligament contains the uterine artery, and one must make sure that the bladder and ureters have been pushed well up out of the way. In this freeing of the broad ligament, rough boring or tearing manipulation must be avoided, and extreme caution and gentleness must be observed, not only because the bladder and ureter may be lacerated, but also to avoid tearing through the larger vessels. The chronic inflammatory processes in the pelvic connective tissue do not leave the vessels unchanged; arterial and peri-arterial, phlebitic and periphlebitic processes may cause an unusual degree of brittleness of the vessel walls.

A clamp with short stout blades is applied to the exposed base of the broad ligament at each side, and the tissue at once cut through inside the forceps. The liberated portion of the uterine neck is then cut upward with the scissors, right and left from the commissure in the coronal plane, making in this way an anterior and posterior flap. One after the other is then drawn forwards, and cut away horizontally from the uterine body, and a fresh volsella placed on the middle of the wound surface of each of the stumps.

In all this cutting the hæmorrhage is practically nil, for the vascular supply has been previously cut off from each transverse uterine segment which is to be extirpated.

We consider it better to give the flaps an oblique instead of a horizontal direction in front of and behind the cervical canal. In this way there is fashioned a tent-shaped cavity, with the apex above, while the tissue sloping downwards at a sharp angle is better adapted for the volsella.

There is now room for further liberation of the uterus, and the process is to be carried as high as possible in front, at the sides, and behind, in exactly the same way as just described. The greatest possible care is to be observed in freeing the anterior wall as long as the bladder and ureters have not been entirely isolated.

Another short heavy clamp is now to be applied above and inside the first, at a height corresponding to the freed portion of the womb, the ligament on each side cut away from the uterus for a like distance, a flap formed in front and behind as was done with the cervix, and then this again cut away transversely. Generally during the second act the anterior fold of peritoneum comes into view as a firm white fibrous membrane. It is to be opened in the usual manner, the finger introduced, and adhesions in the anterior cul-de-sac torn away and adherent loops of gut freed if present. As a rule the posterior cul-de-sac offers the most serious difficulty. Separating the adhesions between the rectum and uterus carefully with the finger during the formation of each flap, it not infrequently happens that the peritoneal cavity is not opened from here until the fundus has been cut away from below (total obliteration of Douglas' pouch).

In completing the total extirpation of the uterus, the further procedures are always a repetition of the first: liberation of a segment of uterus and ligament, preventive clamping of the latter, formation of anterior and posterior flaps by splitting the uterus up along each side, and finally excision of the same. The incision and resection proceed *pari passu* until finally the womb, with all its vessels safely secured, has been so far shelled out that only the lateral horns remain to show the way to the adnexa.

If, however, in the course of this systematic resection the fundus becomes mobile, it is to be at once delivered along with the appendages without further manipulation. Otherwise the extirpation by this method is usually completed in three or four acts with the application of as many clamps on each side.

What is still to be done depends wholly on the condition and position of the adnexa. It would be unnecessary, as

well as dangerous, to force a radical operation when a dense pachypelviperitonitis is encountered in which the uterus and pelvic peritoneum are chiefly involved, whilst the appendages are relatively little altered, or possibly totally atrophied and buried in the pelvic connective tissue, inseparably fused to it and the pelvic wall. Under such circumstances one would only lacerate the pelvic floor in attempting to dig out the adnexa, and perhaps injure the ureters or intestine as well; hence the mere removal of the womb must suffice. By this means, in the first place, the focus of the chronic inflammatory processes, the diseased uterus, is eliminated; and, secondly, with its removal disappears the fixed point for the firm adhesions which bind it to the intestines (more especially the colon), and which seriously affect their function and mobility.

But when fluid collections exist in the appendages (pachypyosalpinx, pyo-ovarium, intra- and extra-peritoneal abscesses) the question is different, for here the radical operation is not only desirable, but is technically possible as well. Happily, the indications and the feasibility go hand in hand.

Beginning at one horn of the uterus, the appendages are brought down into the space left by the removal of the womb, preferably taking first the side which is the easier to enucleate. Two fingers are introduced along the diseased tube, commencing at the isthmus, and this, together with the ovary, is shelled out bluntly, the process being meanwhile aided by traction with an ovum forceps on each successive part as it is freed. On account of the clamps already in place, this method of enucleation demands much greater caution than those previously described. Too rough manipulation in this limited space may lead to loosening or slipping of the clamps controlling the uterine vessels, therefore attempts at bimanual enucleation should be discarded as much as possible.[1]

[1] In a few cases, particularly in narrow vaginæ, after the removal of the uterus, we have joined the several isolated pedicles into one or two larger ones. To the outer side of the clamps first put on, one or two clamps are applied, so that all the small pedicles are grasped as one mass. In this

If difficulties be met with, it is much better to expose the abscesses or pus-tubes by holding back the structures with the retractors and carefully sorting the clamps; then possibly, after evacuating their contents, one may try to loosen and bring out their upper portions. The larger the mass of diseased adnexa adherent to the uterus, and the nearer they lie to the recto-uterine cul-de-sac, the easier is their enucleation. Often they can be delivered *in toto*. At other times, however, they can only be got away in larger or smaller pieces.

Occasionally by the purely vaginal method only a partial extirpation of the diseased tissues can be accomplished, as, for instance, when the adhesions lie more to the sides, when the inflammatory products are high up and posterior, or retroperitoneal and behind the sigmoid flexure, or, finally, when they are situated up against the anterior abdominal wall.

In such cases ventral laparotomy is justified, and with its aid must be accomplished that which could not be done per vaginam. After the incision through the linea alba, the purulent cysts are freed and ligatured, as in a primary laparotomy, or one or more clamps may be passed through the vagina and applied to their pedicles under direct visual control. The intra-abdominal ligatures may be cut short, or they may be used to drag the stumps down into the vaginal wound. Sometimes the control of the vessels during the preceding vaginal operation is so effective that in the ventral laparotomy the adnexa can be shelled out of their adhesions with no hæmostatic measures, and without losing a drop of blood. As soon as all the diseased tissues have been removed, the abdominal wound is to be closed, and the vaginal wound surface examined.

---

way one gains considerable space for the enucleation of the appendages. The width of the wound is correspondingly increased by the removal of the forceps, securing in this way a better exit for the discharges. This uniting of the pedicles can be practised in the same way in all the other methods of the vaginal radical operation, especially when it is desirable to reduce the weight of the bundle of clamps after the operation. At the same time the pedicles are shortened, and large masses of tissue removed which would otherwise have to come away by themselves.

There may be considerable parenchymatous hæmorrhage from the shreds of adhesions and remnants of pyogenic membrane.

Compression with a mounted sponge for a short time usually stops the oozing, but in other cases short light clamps must be applied. After the operation is finished, the central strip of gauze is to be loosely spread over the whole ragged and lacerated wound surface.

It must be admitted that in many cases, even after the ventral has been joined to the vaginal laparotomy, the adnexa cannot be reached, because the intestines fused together by the chronic general peritonitis form an impenetrable roof over the internal genitalia. To isolate gut and adnexa from each other, and from the pelvic and abdominal walls, means nothing less than laceration. Such cases cannot be radically dealt with by any method.

Here, forced by necessity, one must be content with a hysterectomy with evacuation and drainage of the abscesses into the vagina. All the remaining recesses and spaces are to be loosely packed with gauze. Portions of abscess walls must likewise be left behind regardless of their extraperitoneal development, when their capsule is in part formed by a hollow organ (bladder, rectum).

It is evident that here the operation must remain incomplete. So the vaginal radical operation, even in combination with ventral laparotomy, has its limits, and must, when necessary, conclude with the removal of the uterus.

CHAPTER IX.

IRREGULAR MORCELLATION (TRUE MORCELLEMENT).

1. When the Uterus is not at all, or but slightly, enlarged.

The method given for bilateral incision of the uterus with transverse resection cannot be employed when the uterine parenchyma has lost the firmness necessary for the shaping of the individual portions to be removed; for instance, in inflammatory œdema of this organ, found chiefly in pelvic

suppuration following labour or abortion; in extensive tubal pregnancy; and, finally, in many cases of chronic recurrent (so-called subacute) pelvic suppuration.

We shall not here enter into the discussion of the indications for hysterectomy in suppurative puerperal conditions. Some authors (Richelot) regard the puerperal softening and relaxation of the uterine tissue as a direct contra-indication for hysterectomy. We may observe, in passing, that of two cases which we subjected to the vaginal radical operation on account of complicated puerperal pelvic abscesses, one died, and the other was saved in spite of a hopeless prognosis before the operation. In all cases of metritic softening, however, whether puerperal or not, the technical difficulties in the way of uterine extirpation are unusually great, simply because it is impossible to carry out the plan of the operation according to one's own wishes, for the procedure must within certain limits be governed entirely by the consistence of the organ. Naturally, this applies as well to the intended Péan's morcellement, as to all other procedures for extirpating the softened uterus.

The main difficulty lies as much in avoiding hæmorrhage as in controlling it, for the volsellæ, which in other forms of morcellement exert their hæmostatic effect by traction and pressure, are here unavailing, because traction simply lacerates the organ, while compression crushes the tissue. Moreover, in spite of all endeavours to protect the lateral portions of the uterus, the tissue may be lacerated, and the tear extend into the inflamed and highly vascular broad ligament.

Under such circumstances one can scarcely give a typical description of such an operation even if Péan's morcellement is to be aimed at throughout. Sometimes it would vary but little from the classical Péan's operation; sometimes in its unforeseen irregularity it would not resemble it in the least.

The indications have already been mentioned; the softened uterus must not exceed the size of a man's fist.

At the very beginning of the operation, in applying and making traction upon the volsellæ, or in denuding the cervix, it becomes evident that, in spite of the ease with which the

œdematous paracervical tissue is separated, the forceps will not hold, and that the portio tears and crumbles away. The same difficulty in getting a firm hold in the tissues which one meets with everywhere makes it impossible to resect the uterus in a regular geometrical fashion. It is best to dissect bluntly with the fingers, keeping always to the sides, for in spite of all this difficulty one must endeavour to apply the clamps regularly and evenly, working upwards from the broad ligament.

Whenever the consistence of the tissue allows, the original

FIG. 44.—VAGINAL RADICAL OPERATION, WITH IRREGULAR MORCELLATION OF A UTERUS ONLY SLIGHTLY ENLARGED.

Péan method should be again resorted to. Not infrequently, however, and contrary to the operator's wishes, the flap on the posterior or anterior wall, or both, tears out with the volsellæ, and one must then be content with small pieces of uterine parenchyma during the further resection of the organ. After primary control of the vessels and the longitudinal incision at the sides, the two flaps are to be dissected away as small cubical or irregular fragments, removed by vertical or oblique incision. Or after primarily clamping the ligament and severing the corresponding segment of the uterus, the bilateral splitting can be omitted, and the

separated portion cut away in all manner of small polyhedric bits. This latter procedure, which we often employ, is well illustrated in Fig. 44.

When necessary, the sound may be used to show the position and direction of the uterine canal.

If the parenchyma bleeds profusely, hæmostatic forceps can in some cases be applied to the softened myometrium itself.

In this way, avoiding all rough traction and manipulation of the clamps when they have been once applied, after the customary opening of the peritoneum in front and behind, the fundus is reached and delivered in the same manner.

The field is now clear for the enucleation of the adnexa, and this is to be accomplished in the usual way.

2. When the Uterus is enlarged, or, if normal, in combination with a Narrow Vagina.

We have now reached a description of the methods which alone render vaginal hysterectomy possible, when the uterus is larger than a child's head.

This procedure is indicated chiefly in single or multiple fibroids, from the size of a fœtal head upwards, with or without complicating inflammatory or suppurative diseases, or genuine tumours of the adnexa. The myomatous uterus may be pushed up into the abdominal cavity, or walled in by surrounding collections of pus.

In the sense of its being an indication for this operation, the size of the uterus is naturally a relative term, and is to be estimated by the space relations between it and the vagina. Hence, irregular morcellation is employed when a normal or but slightly-enlarged uterus has to be removed through a narrow vagina, other forms of dissection not giving the necessary room without attacking the adjacent structures (perineal incision, etc.). One condition that is necessarily implied in the indication is that less mutilating conservative procedures are not applicable; in other words, the circumstances are such that the uterus must be sacrificed. Included in the list of conservative methods are the cases of

enucleation of a fibroma after it has been previously partly dissected away (morcellating myomectomy).

Contra-indications are: first, uterine fibroids extending beyond the navel; secondly, tumours of the body of the uterus, whose development is chiefly or wholly subperitoneal. In the first, abdominal or abdomino-vaginal hystero-myomectomy is to be employed; for the second, simple abdominal resection or enucleation; or, finally, abdominal total extirpation. The latter is required when a conservative procedure is impossible, and the distance of the tumour from the vaginal vault is so great that no portion of it can be pushed or drawn down into the vagina.

In each of these morcellating operations, the governing idea throughout is not to hold fast to mathematical lines, but simply to dissect away the whole mass in the safest and most convenient manner adapted to the case at hand. For the morcellement, the uterus and the myoma or myomata form one inseparable block.

The individual masses to be removed must always correspond to the dimensions of the natural obstetrical canal, so that all further injuries from dilatation may be avoided. The size of each mass is therefore directly dependent on the width of the vagina.

In this procedure the volsellæ are of paramount importance. Their two-fold action in the control of hæmorrhage, namely, by compression and traction, is here specially exerted. Besides this, they have to hold the fragments which are about to be removed, and at the same time control the edges of the wound left behind, otherwise a flap of the wound might slip away, and from the incomplete compression a dangerous hæmorrhage might result. While they secure the old field of operation, they mark at the same time the line of the new territory to be invaded.

It is quite immaterial what instrument be chosen to dissect the uterus or uterine tumour, whether it be the serre-nœud, écraseur, or knife and scissors. For our part we use the long scissors and knife, both straight and curved.

The difficulty in describing the forms of morcellement in a systematic way consists manifestly in the countless varieties

of kind, number, size, and seat of the myomata. In this respect there are as many kinds of morcellation as there are anatomically different conditions; *i.e.*, they are innumerable.

Many who have seen a number of morcellating operations will be forced to the conclusion that they have witnessed nothing more than a mere laying hold and cutting, seizing with forceps and again cutting, etc.—in short, a somewhat irregular and arbitrary procedure, not depending on any definite rules beyond patience and physical strength. And yet such an opinion is entirely incorrect. As a matter of fact, a mere aimless seizing and cutting here and there would scarcely accomplish the desired result; on the contrary, even here there are, as stated, certain broad principles which must be very exactly observed, and definite methods whose characteristics are quite different from each other, although they may often be combined to good advantage.

CHAPTER X.

THE DIFFERENT FORMS OF IRREGULAR MORCELLEMENT EMPLOYED ON THE ENLARGED UTERUS.

In classifying these procedures according to the kind of hæmostasis employed, three groups of operations are to be distinguished, namely: those in which the hæmostasis is preventive, those in which it is consecutive, and those in which the two procedures are combined. The relations between morcellement and hæmostasis have been previously referred to (see p. 51). We stated there that morcellement and preventive hæmostasis have as little relation to each other as have morcellement and the clamp method. Wherever it is possible in these morcellating operations, we adhere to the principle of *consecutive* control of the vessels, pushing directly into the centre of the mass to be extirpated, avoiding, meanwhile, the vascular periphery of the tumour and the lateral portion of the uterus. The leading aim is to proceed at once with the removal of masses wherever it is most convenient, and then deliver and pediculate the remaining parts without

first securing the vessels, the hæmostasis therefore following, and occupying a secondary place.

In a second group of cases the vessels must be clamped primarily; such are the cases in which a myomatous uterus is immobilized directly by the tumour itself, or by perimetritic adhesions, or indirectly by the diseased adnexa; in these the fixation remains unchanged up to the end of the hysterectomy, no matter how much of the lower segment may have been cut away under preventive clamping.

The cases which demand primary hæmostasis during the whole of the operation are infrequent, while those in which the mixed form is required are quite common. By the mixed form are meant the cases in which preventive securing of the vessels is necessary only up to a certain point in the operation, after which the organs become mobile, and can then be delivered primarily. This method of hæmostasis comes into use in operations where the fixation is gradually overcome by separating the adhesions, or by further morcellement after the normal or myomatous cervix has been resected; also where a large myoma of the body can be so cut away after the removal of the uterine neck that the fundus, now reduced in volume, can be delivered into the vagina.

Sometimes, however, the operation must begin at once with this morcellation, where, for instance, one has to deal with a large cervical tumour or tumours lying in front of or behind or at the side of this portion of the uterus, or where a segment of a submucous fibroid already occupies the cervix, widely distending the canal.

Each of the three groups of morcellating operations may be further subdivided into two minor classes: morcellation by means of centripetal resection, and morcellation by means of centrifugal excavation. In the first group, wedge-shaped masses are resected from the parenchyma or periphery of the mass, *toward* the centre. In the second, the tumour is excavated or bored out *from* the middle, Segond's 'central excavation' in the proper sense of the word. As a variety of this method is to be reckoned the enucleation of fibroids, either whole or partially dissected by one of these two methods. It is obvious that the latter form of morcellement is the one to be em-

ployed on the uterus whenever possible, and that during the dissection one should endeavour to cut away as large masses as possible.

The centripetal method is really nothing else than a modified form of the morcellation described under the V-, Y-, and parallel incision.

The size and position of the tumours do not generally allow of a symmetrical plan of incision definitely repeated, with the resection of masses of regular size and shape. A long scissors or knife is used, and irregular blocks are cut out one after the other in different wedge-like forms, until finally the whole mass has been reduced to the size necessary for its delivery. The dissection of the tumour or uterus begins at the exposed surface, just as in the symmetrical morcellement, and here also the incisions are not always carried through the whole thickness of the tumour or myometrium.

Just where one must begin depends wholly on the seat of the tumour, whether the anterior, posterior or lateral aspect of the uterus is to be cut away, whether the tumour is to be attacked from its peritoneal surface, or whether its periphery can be reached after previously splitting the myo- or endometrium, in the latter case working within the uterine cavity, through the mucosa.

The technique of the centripetal method consists in bringing the surface of the mass into view, freeing it from all connections with adjacent organs, and then commencing work by resecting a large wedge of the tumour with the long knife or scissors (Fig. 45). Volsellæ are placed on the edges of the wound immediately after the incision, so as to avoid the danger of the stump retracting and becoming lost. In beginning on the serosa, one may at the same time have to free the tissue in the grasp of the forceps from adhesions to neighbouring organs. The edges so fastened are pulled downward, a fresh portion of the tumour is brought into the vagina by forceps applied higher, and this piecemeal extirpation is continued in the same way, resecting wedge- or cone-shaped masses until the stump is small enough to pass the vaginal outlet.

In distinction to this form of morcellement, in which the

tumour is attacked from its periphery, the second method, Segond's 'excavation,' begins with the central portion of the tumour. In this a crater is formed which is continually enlarged, undermining the periphery, and finally bringing it to collapse. In some cases, after clearing out the inner portions, the whole organ is reduced to a loose movable sack resembling the eviscerated fœtal body. The base of the

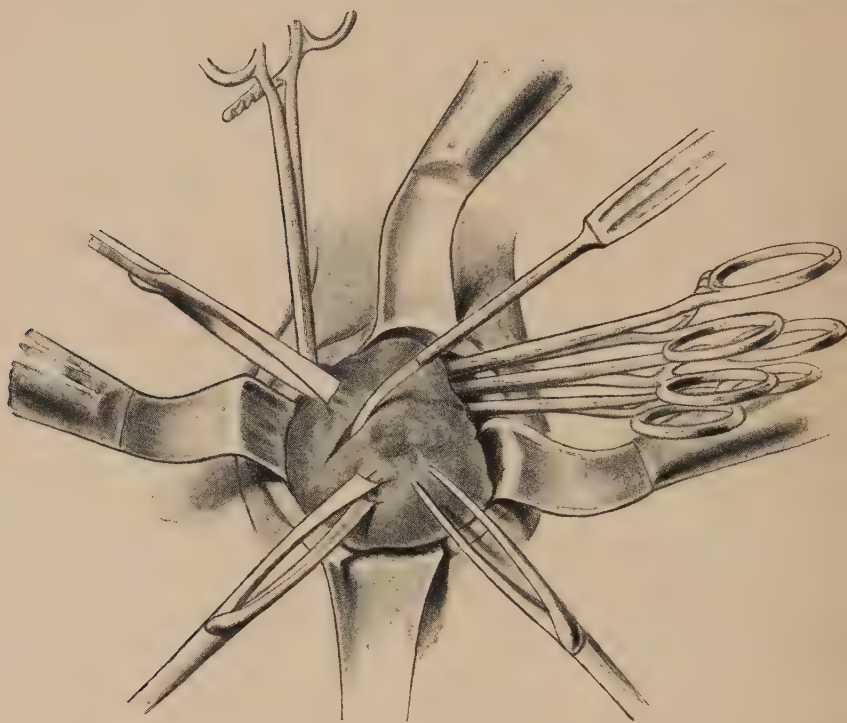

FIG. 45.—CENTRIPETAL MORCELLEMENT OF A FIBROID OF THE BODY OF THE UTERUS.

On the left side the cervix has been separated from the broad ligament; and here three preventive clamps have been applied.

conical cavity is, of course, directed towards the periphery, hence the first incision must begin at the other surface of the tumour.

Thus, in the central excavation the details of the procedure consist simply in the digging out of a hollow cone, whose apex is directed toward the middle of the tumour; the base

is begun first, and forceps are then placed on the edge of the circular incision. Then one or two new forceps are placed deeper in the cavity, and a further segment is cut away towards the centre of the mass. The volsellæ are again applied, fresh portions of the tumour are brought into view and corresponding wedges and cones excised, and canals and furrows scooped out and again reunited. One mass of muscular tissue is removed after the other, working always in the intramural and subperitoneal regions.

The size of these blocks of tissue depends wholly on the thickness of the uterine wall.

Some operators employ trephine-like instruments of various construction for this boring and excavating process.

That these two forms of morcellement are often combined is readily understood from the nature of the thing. Not infrequently after the central excavation, it is possible to bring the more or less enlarged uterus forwards by traction on the volsellæ. To further displace it into the vagina, it may be necessary to reduce it still further by cutting away another piece or two from its exposed periphery, thus changing over to the centripetal irregular morcellement.

CHAPTER XI.

THE AVOIDANCE OF HÆMORRHAGE AND INJURY TO NEIGHBOURING ORGANS DURING MORCELLEMENT.

THE chief dangers in all these morcellating operations are hæmorrhage and injury of the adjacent structures.

In regard to the latter, one must hold strictly to the general rule, freeing the bladder and ureters completely from the lower uterine segment whenever it is possible, before beginning the morcellement; and where difficulties are encountered in this line, the urinary organs should be most carefully guarded by retractors. Only after the peritoneum is opened can this vigilance be relaxed, although the exact time at which this is accomplished is in itself indefinite, and varies according to the relations of the individual cases. The method of opening the posterior cul-de-sac is governed

by the rules previously given, modified always by the anatomical conditions present. It sometimes happens also that this incision may be one of the later acts, in fact quite the last act, of the operation.

The great danger of injuring the urinary organs when the portio is absent—from atrophy, malignant erosion, or amputation—may be still further increased by myomata in the lower segment of the womb, causing displacement of bladder and ureters. In such cases it is advantageous and much safer to work at first chiefly upon the posterior wall of the uterus. In the absence of the portio, such unfavourable conditions may be present with reference to injury of the adjacent organs that from this cause alone one must sometimes dispense with a vaginal operation.

How the neighbouring organs may be endangered by fibroids is aptly shown by one of Chrobak's cases published lately by Fabricius, in an operation for a myoma situated in the posterior wall of the cervix: the left ureter had to be followed into the tumour and liberated for a distance of 7 cm.

The danger of hæmorrhage only occurs when one works too close to the lateral portions of the uterus, thus approaching the larger vessels of the ligament, or when one neglects to secure the stump against retraction during morcellement. As so often mentioned, the volsellæ here fulfil their important hæmostatic function in a most excellent manner through traction and compression, and therefore the operator is always safe from hæmorrhage as long as he has the uterus under his control.

In morcellement it may be laid down as a rule, always to secure the edges of the wound each time with the fixation forceps before cutting away the portion to be extirpated. In case they cannot be applied in the identical place, a new position is to be sought for higher up, and a firm hold here obtained.

CHAPTER XII.

COMBINED METHODS.

THE foregoing classification of the vaginal radical operation according to its different methods is not merely theoretical, but is really based on our experience of a series of 470 operations. Those who have at their command the various methods described, will in every case of vaginal extirpation be able to master all the difficulties encountered. Naturally, one is sometimes obliged to employ a combination of these different forms of extirpation—that is, to resort to a mixed procedure. Here, also, the guiding principle is the use of preventive hæmostasis and secondary enucleation *only* as a method of necessity. In all cases the aim is to form the pedicles under visual control, and secure them *secondarily*.

Under preventive hæmostasis we have often first sacrificed the cervix, extirpating it entire, or after section of one or both walls. Then, after breaking up the fixation, which is here chiefly pericervical, the stump becomes more mobile, and the rest of the womb, with the adnexa, may be delivered entire or after section of one or both walls, or after morcellation with the Y incisions.

Fig. 46 shows the internal genital organs removed according to a mixed procedure: the cervical vessels secured primarily, the anterior cervical wall split, and the uterine neck then amputated, followed by total median section of the body of the uterus.

Those operations in which the vaginal and abdominal methods of extirpation are united, are mixed procedures in an entirely different sense from the ones in which different vaginal methods are combined. Abdominal laparotomy is combined with vaginal hysterectomy in order to complete the radical operation, or else it precedes the extirpation of the organs per vaginam—vagino-abdominal or abdomino-vaginal radical operation.

With regard to the latter, the operation is begun with the

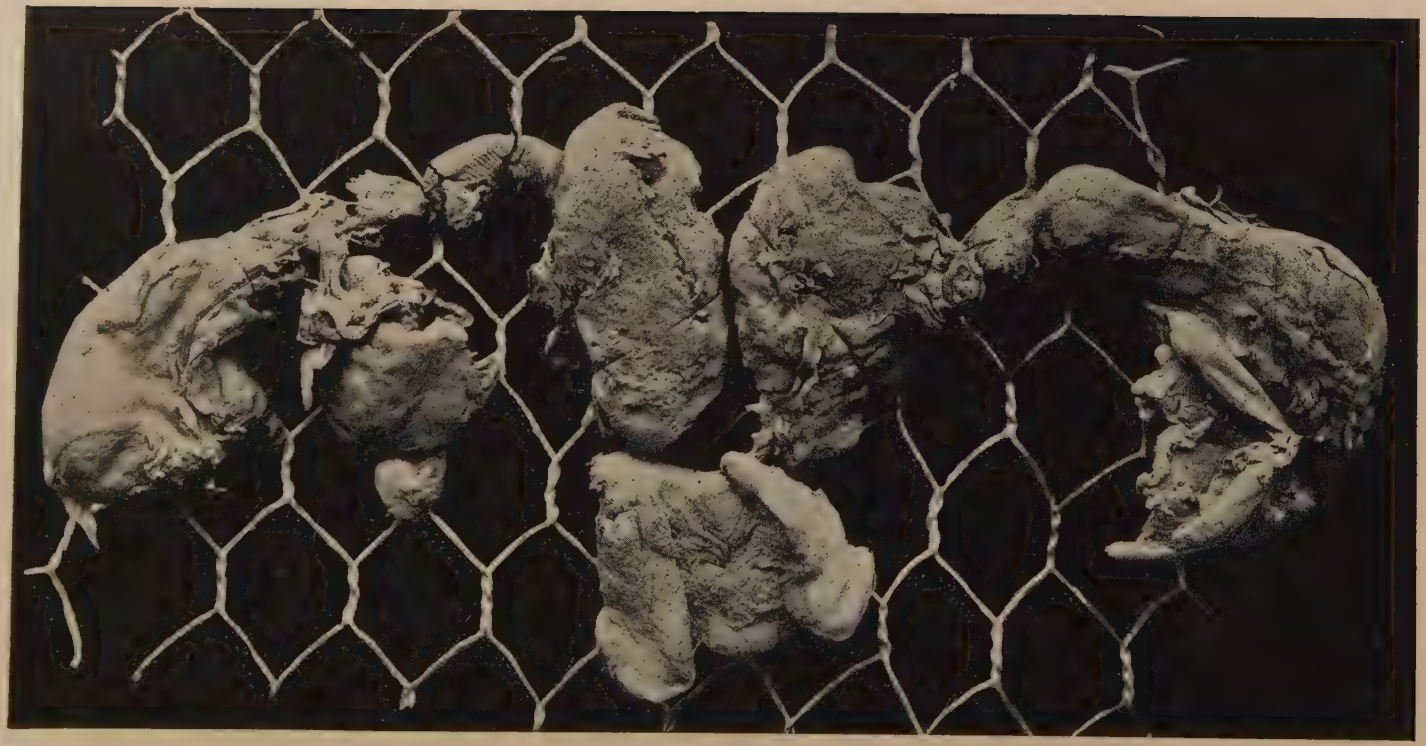

Fig. 46.—Vaginal Radical Operation by the Mixed Procedure.



Fig. 47.—Abdomino-Vaginal Radical Operation.

incision through the linea alba, really not for technical, but rather for diagnostic purposes (duplicity of organs, dissemination of malignant tumours, etc.). After the belly is opened and the indication for a vaginal radical operation established, this primary ventral incision can be utilized for freeing the uterus and adnexa from adhesions under direct visual control, making the organs mobile for the vaginal extirpation.

After liberating and shelling out the appendages, one can ligature and remove the diseased organs just as in a primary ventral laparotomy, without regard to the proposed vaginal extirpation which is to follow. In some cases the vaginal hysterectomy is in this way greatly simplified.

In the case illustrated by Fig. 47, the diagnosis was made of a large unilateral (right) suppurating ovarian cyst lying mainly in front of the uterus, and against the abdominal wall. The extirpation was begun with the ventral incision. The tumour was found to be a gigantic tubo-ovarian abscess, and on the other side an extensive pelvi-peritonitis with a pyosalpinx was found, and the vaginal radical operation was then decided upon. In the endeavour to bring the right tumour up into view, it was loosened from its surroundings, and could be shelled out and removed entire. The ventral wound was closed, and the uterus, which could now be removed in one mass (without morcellation), was extirpated through the vagina along with the adnexa of the left side.

Had the vaginal extirpation been primarily adopted in this case, a much more complicated method (morcellement) would have had to be employed.

PART III.

THE AFTER-TREATMENT.

CHAPTER I.

AFTER-FEEDING—REGULATION OF BOWELS AND BLADDER—TEMPERATURE—SECONDARY HÆMORRHAGE.

THE measures which follow every vaginal radical operation until the patient is placed in bed have been described (Part I., Chapter III.). The bed has been previously warmed by hot-water bottles. After operations of unusual duration or severity, and especially in the case of anæmic patients, as in myoma or carcinoma, we employ the usual stimulants: several hypodermic injections of ether and camphor; subcutaneous or rectal injection of normal salt solution; or brandy, hot tea or coffee in small doses by the mouth.

Otherwise nothing is given the patient during the first five hours, except a little water for rinsing the mouth. For the thirst and nausea a small cloth moistened with dilute vinegar is laid over the mouth. After this time she receives a sip of cool coffee from time to time; for inordinate thirst or nausea, small pieces of ice.

We have often persuaded intelligent patients to swallow nothing at all during the first twenty-four hours, with the certain result that vomiting was entirely absent.

Vomiting immediately after the operation occurs relatively seldom, in many cases not at all. Later, however, during the first and second day, it is not uncommon.

If the twenty-four hours' abstinence cannot be enforced,

one may give a little water with red wine during the first night, and on the following morning coffee with a little milk. For breakfast and dinner we allow oatmeal gruel also, in the afternoon coffee and milk, in the evening a little weak soup. Except in the case of weak and debilitated patients, we usually dispense with alcoholic preparations, such as wine, champagne, and cognac. On the third day the same diet as just given.

In the ordinary course, flatulence, borborygmi, and abdominal pain begin on the third day. Infusion of caraway, peppermint, or valerian relieves the flatus, which, as a rule, is got rid of during the third day or night. The pain due to this gaseous distension is satisfactorily met by placing on the abdomen hot or cold compresses, or the ice-bladder, according to the individual preference.

On the fourth day the diet is the same as on the second and third, or, if the general condition is exceptionally good, soft biscuits or rusks. On the fifth and sixth day bouillon for dinner, with rusks or biscuits.

The bowels often move spontaneously on the fifth day; if there is severe rectal tenesmus, it is relieved by an injection of warm water. In any case, however, the patient receives on the morning of the seventh day two tablespoonfuls of castor-oil, given in beer foam or hot coffee. During the further convalescence care is taken to secure a regular action of the bowels.

From the seventh day onwards the convalescent receives the usual light and easily-digested diet—coffee, milk, bouillon, oatmeal gruel, white bread, rusks, chicken, calf's brain, fish, roasted potato, and stewed fruit.

Vomiting, if it occurs at all, generally ceases when the tympanites is relieved—that is, on the third or fourth day. Occasionally at this time alarming symptoms of ileus occur, marked by vomiting, distension of the belly, colicky pains, and weak pulse. In certain cases the removal of the gauze strips from the vagina suffices to allay these stormy symptoms. At other times the disturbed intestinal tract can be restored to its normal condition by rectal injection or flushing of the colon. For ordinary vomiting, as well as for obstinate hyperemesis, washing out the stomach, repeated if neces-

sary, has rendered us very valuable service. In spite of the unpleasant nature of this manipulation, the patients are always so much relieved by it that of their own accord they frequently demand its repetition. Several times in obstinate vomiting, on the fourth or fifth day, it has been observed that fluids were all rejected, while solid food, such as biscuits and rusks, was well retained.

This pseudo-ileus is probably due to fresh and weak adhesions, and incarceration of intestinal loops in the neighbourhood of the wound, which are broken up again by peristalsis, or by the filling of the colon with water (injection, irrigation). During the remainder of convalescence, here as after every case of major operation, vomiting due to errors of diet is much more readily started than controlled.

But taking it altogether, the unpleasant symptoms arising from the intestinal tract are much less than those after abdominal laparotomy for inflammatory affections; and besides this, the whole course of recovery is much more rapid, whilst post-operative shock is practically absent. After the bowels have been evacuated, it is often difficult to keep the patient longer in bed.

Pain, which occurs in most, though not in all cases, is treated by hypodermic injections of morphia. As soon as the patient awakes from the anæsthesia and complains of pain, she receives a hypodermic injection of gramme 0·01 ($\frac{1}{6}$ grain). Further injections are given as required, and generally gramme 0·03($\frac{1}{2}$ grain) suffices for the first twenty-four hours. In ordering the quantity to last during the night, we have found it more serviceable to divide it into two doses of $\frac{1}{10}$ grain each than to give the whole at one time. It is scarcely ever necessary to continue the drug beyond the first or second day.

To damn the whole clamp method as a 'torture,' on account of the pain following the operation, is nothing less than an empty fiction; as Richelot rightly says:[1] 'C'est faire un véritable roman que de décrire comme un supplice l'opération nouvelle.'

The patient is catheterized as long as the forceps are left on; either the permanent catheter is left in the bladder

[1] L. G. Richelot, 'Archiv. générales de Médecine,' Juin, Juillet, 1893.

until the clamps are removed, or else the urine is drawn off with a long metal catheter every six hours. Many patients have surprised us by being able to urinate spontaneously in the course of the first day. The reason that the urine is artificially drawn off in all cases during the time the clamps remain is principally to avoid the pulling about and moving of the clamps while the pelvis is being lifted on to the bed-pan or other receptacle. Only in the most exceptional cases is it necessary to use the catheter a day or two after the clamps are taken away.

Contrary to the practice of other operators, we have often removed the clamps after the first twenty-four hours. But although we have never known this early removal to be followed by any hæmorrhage worth mentioning, as a rule we still leave the forceps in place forty-eight hours.

The clamps are removed with the patient in bed; the only change in her position is that the thighs are raised and the knees separated a little. The surgeon stands at the right side of the bed, and passes his left arm under the patient's right knee, lifting the instruments gently from below. Then, with the right hand between the patient's thighs, one clamp after the other is unlocked, and after waiting a moment with each one, so as to relock it if necessary, it is pulled away with a cautious twisting movement.

If in occasional cases there is a slight trickling of blood from the vagina, the introduction of a cotton-wool tampon within the vulva is generally sufficient to stop it. If it persists in spite of this, it is sometimes necessary to bring the patient across the bed, and, after removal of the gauze from the vagina, to seek out the bleeding-points and clamp them again. The bleeding in such cases comes from the paracervical plexus of veins, or from the incision in the posterior vaginal wall. After this renewed clamping, gauze is introduced, and the forceps left in place twenty-four hours longer. We would particularly warn against a mere gauze tamponade in such cases, for it may change the external bleeding into an internal and invisible one.

Frequently one of the lateral gauze strips is pulled out with the clamps when they are removed. In reference to

the others, more particularly the central one, we have decided after many experiments to leave them in place until the evening of the fifth day. They are taken out before this time only in case symptoms of obstruction develop, sometimes on the fourth, or even third, day.

It is yet to be determined whether the use of the gauze for drainage during these five days is really of such importance, and we think it is probable that this exact length of time may be varied to some extent without injury to the patient. Probably the chief function of the gauze consists in its action as an irritant to the whole wound surface, causing its rapid encapsulation. Doyen, for instance, who in some cases removes all the strips within twenty-four hours, has just as good results as Richelot, who usually leaves cotton-wool tampons in the vagina for seven or eight days.

We have but seldom seen hæmorrhage following the removal of firmly-adherent gauze, either immediately or after several hours. Such bleeding would be easily checked by introducing a fresh strip. There is no fear now that this manœuvre will change the external into an internal hæmorrhage, because by the fifth day the abdominal cavity is already closed off. We consider cold irrigation as a styptic unnecessary, and a waste of time; we abhor perchloride of iron here as everywhere else.

We do not regard elevation of temperature during the first few days as an indication for the early removal of the gauze. An evening temperature a few points above 100° F. (38° C.) is the rule in the first week, and, indeed, sometimes it reaches 102° F. (39° C.), in cases whose progress is entirely satisfactory in all other respects. Generally the curve reaches the normal only after the seventh day. A rise of temperature on the fourth to sixth day merely indicates the demarcation of the scar, and the good general condition of the patients coincides with this hypothesis. The temperature has been ascribed by some to fæcal retention, and many operators—for instance, Segond—have the bowels moved by a glycerine enema on the evening of the third day, a few hours after taking off the clamps. Our answer to this is that frequently in our cases the temperature comes

down of itself before the evacuation of the bowels. We have never observed a threatening rise of temperature to 104° F. (40° C.), with disturbed general condition, in the first week, probably because in our vaginal operations we do not leave cavities and spaces in which retention of pus or secretions can occur. Therefore all the manipulations which others have recommended and practised to prevent stasis of the secretion and 'surgical fever' in the first few days, have no interest for us. Lafourcade examines such cases with a Fergusson's cylindrical speculum, and removes the eschars under visual control, and in case of the escape of large gangrenous masses he employs a new drainage of iodoform gauze.

For our part, all that we do is to wait twenty-four hours after the removal of the gauze, generally on the evening of the sixth day, and then begin vaginal irrigation with sterilized lukewarm water once or, if the discharge be profuse, twice daily under very slight pressure. Although we have had no personal experience in the matter, we would join in the warning given by others not to use the irrigation too soon—that is, immediately after removing the gauze—and not to use any considerable pressure in the irrigation. Severe local peritoneal irritation, as well as syncope (Segond), have been observed as a result of such procedures.

From the eighth to the twelfth day the discharge is especially profuse, foul-smelling and dirty-coloured. During this time the discharge and the irrigation fluid contain abundant masses of necrotic and decomposing tissue shreds.

About the fourteenth to sixteenth day with the majority of the patients, the irrigation fluid comes away clear, and shortly after that, the last traces of the discharge disappear. In other cases there may be a catarrhal secretion for four to eight weeks more. Where the operation has necessarily been incomplete—that is, where portions of pyosalpinx or pelvic abscesses had to be left behind—the discharge will, of course, continue until these secreting fistulæ and surfaces have become obliterated, a process which may take several months. Still, this unpleasant occurrence is but a slight memento of the previous objective and subjective symptoms which the operation has relieved.

Although we have not had the opportunity of getting a direct view with a speculum of the healing process taking place in the vaginal vault, we can still assert that its union, *i.e.*, the closure of the peritoneal cavity and the isolation of the vaginal wound from the latter, must be completed within a very few days. In one case, the digital examination of a patient on the seventh day showed that the vagina was completely shut off by thin soft and uneven granulation tissue with a slightly-indurated margin. When the convalescent patient is examined prior to her discharge—that is, about the end of the third week after the operation—one finds in the dome-shaped vagina a soft linear cicatrix surrounded by radiating folds. Later it becomes firm, and is often hard to differentiate. Avoidance of sexual intercourse during the first eight weeks is ordered, for the protection of the cicatrix.

Instead of the typical convalescence just pictured, it occasionally happens that a patient at the end of the first week complains of temporary or continuous pain in the lower abdomen, and develops fever. We have had these undesirable symptoms in a few cases where we were compelled to leave the operation incomplete, allowing suppurating pockets or spaces, or pieces of suppurating tube, to remain. In such cases we abandoned the usual expectant after-treatment, and tried by means of cautious exploration and dilatation with the finger to make a free outlet in the vaginal vault for the stagnant discharges, and with the best results. Secondary drainage or tamponade was not employed.

At another time, just before commencing this exploration, we observed a spontaneous evacuation of watery sero-purulent fluid in such a profuse quantity as to almost make one think of a sudden vesical incontinence. As we afterwards demonstrated, there had been formed in the vaginal vault a conglomerate mass of peritoneal cysts.

In another case the convalescence after the vaginal radical operation was very markedly delayed. Here, following a complicated pelvic abscess in a virgo intacta (no gonococci, no tubercle bacilli), there slowly developed a board-like infiltration of the preperitoneal cellular tissue, which progressed for weeks, and finally extended over the whole

abdominal wall up to the ensiform cartilage. The slightest touch on the overlying skin, although not inflamed, or even reddened, was extremely painful. Repeated incisions and the course of recovery itself showed that it was not a purulent or phlegmonous inflammation, but really an œdematous induration and gelatinous infiltration of the intensely reddened and swollen preperitoneal tissue. The process subsided of itself after three months, the fever disappeared, and the patient, who is now in blooming health, presents no trace of the serious and extensive affection of her abdominal wall.

We have seen two other rudimentary examples of this apparently as yet undescribed process, each time involving the preperitoneal tissue, but of much less extent and gravity, and of shorter duration.

A certain amount of active treatment may be required on account of secondary hæmorrhage, which, if it happens at all, occurs generally on the eleventh to thirteenth day. Once, in a previously uneventful recovery, it occurred on the fourteenth day. Curiously enough, the severest of all our secondary hæmorrhages occurred several years ago in a patient operated on by the ligature method. It is as yet uncertain whether these hæmorrhages are due to the separation of large sloughs or dependent on the menstrual period, or both. At any rate, the simple tamponade is sufficient in such cases.

After the tenth day we allow the patient—who up to this time has maintained the horizontal posture—to vary her position as she may desire: to lie upon the side, to be raised somewhat, and to move about in bed very cautiously. In this respect we have often been anticipated by lively patients, who, when the chance offered, got out of bed as early as the fifth or sixth day, for instance, to be able to urinate more conveniently.

On the sixteenth to eighteenth day the patient is allowed out of bed, and there is nothing to hinder her discharge within a few days more. It is advisable to have the vaginal irrigation continued once daily for several weeks more at home.

From the foregoing regulations for the after-treatment, the chief principle during this time may be considered to be *the greatest possible inactivity.*

EXPLANATION OF THE ILLUSTRATIONS.

THE instruments (Figs. 1 to 16) are drawn according to nature. The plates 19, 24, 25, 26, 27, 34, 36, 37, 41, 42, 43, are diagrammatic. The process adopted for the others was as follows: During the various stages of the operation photographs were taken, and from these, large drawings were made, which were reproduced again on a smaller scale for the plates.

Figs. 39, 40, 44, 46, 47, are reproduced exactly according to the photographs of the preparations.

The following are the clinical and anatomical data concerning these plates:

FIG. 39.—VAGINAL RADICAL OPERATION WITH TOTAL MEDIAN SECTION OF THE UTERUS.

L. K., nullipara, 37 years old. Ill seven years; profuse discharge; oppressive pain and throbbing in both sides of lower abdomen, radiating toward the thighs; severe pain in the back. Patient comes to the clinic because she is so greatly reduced by her illness and cannot follow her vocation.

Operation, June 14, 1894. Pachypelviperitonitis with formation of serous cysts, double pachypyosalpinx. Cystic degeneration of both ovaries. Large intra-ligamentous cyst on the left side. Permanently cured.

FIG. 40.—VAGINAL RADICAL OPERATION WITH TOTAL MEDIAN SECTION OF THE UTERUS.

E. B., primipara, 28 years old. One child seven years ago; ill ever since. Suffers from severe pain in lower abdomen; pressure on the rectum; profuse discharge. Fever for a long time. All previous medical treatment unavailing. Received into the clinic May 31, 1894.

Operation, June 6, 1894. Double pachypyosalpinx. Bilateral ovarian abscesses—single on the right side, multiple on the left. Pachypelviperitonitis with multiple abscesses. Permanent cure.

FIG. 44.—VAGINAL RADICAL OPERATION WITH IRREGULAR MORCELLEMENT OF THE SLIGHTLY-ENLARGED UTERUS.

M. N., nullipara, 30 years old. Trouble in lower abdomen during the last four years. Only temporarily able to work, then confined to bed

again two to five weeks with pelvic inflammation ; agonizing pain, especially in left side, with fever. Medical treatment without result.

Operation, July 1, 1895. Large and strikingly soft uterus. Bilateral tubo-ovarian abscesses. Pachypelviperitonitic adhesions with serous and purulent cysts. Right adnexa morcellated. Permanent cure.

FIG. 46.—VAGINAL RADICAL OPERATION ACCORDING TO THE MIXED METHOD: MEDIAN SECTION OF THE ANTERIOR CERVICAL WALL—RESECTION OF THE CERVIX AFTER PREVENTIVE HÆMOSTASIS—MEDIAN TOTAL SECTION OF UTERUS.

M. K., nullipara, 29 years old. Contracted gonorrhœa nine years ago. One abortion, three weeks' hospital treatment therefor. Since then has not been free from pain in lower abdomen, especially on the right side. Pain radiating towards the legs. In the last few years has had many attacks of pelvic inflammation, accompanied by fever, and confining her for weeks in bed, sometimes at home, sometimes in a hospital. During the previous three weeks was again in bed with severe pain in lower abdomen, and fever.

Operation, February 5, 1895. Pachypelviperitonitic adhesions with intra-peritoneal abscesses. Pus-tube on both sides, cystic degeneration of both ovaries. Permanent cure.

FIG. 47.—ABDOMINO-VAGINAL RADICAL OPERATION (SEE P. 164)—RIGHT ADNEXA DELIVERED BY VENTRAL LAPAROTOMY, THE LEFT TUBE AND OVARY, TOGETHER WITH THE UTERUS, REMOVED PER VAGINAM.

J. S., nullipara, 35 years old. Peritonitis at the age of seventeen. Menstruation during the next year exceedingly painful. During the last ten years is said to have had constant inflammation of the womb, with profuse discharge and pain in the back. Has undergone ten different 'cures' in as many bath resorts and springs. Her trouble has lately been decided by a very eminent authority to be due to an ovarian tumour with a twisted pedicle.

After unsuccessful stay in a number of sanatoriums was brought to the clinic.

Operation, November 15, 1894. Gigantic pyosalpinx of the right side; pachypyosalpingitis of the left side. General pelvic peritonitis with serous cysts. Permanent cure.

THE END.

Baillière, Tindall & Cox, King William Street, Strand.

KW-010-859